KIMPTON'S STUDENTS ESSENTIALS

ESSENTIALS OF GYNÆCOLOGY

EDWIN B. CRAGIN, M.D.

QUESTIONS AND ANSWERS

J. F. Gill

NOW READY.

NEW AND REVISED ILLUSTRATED EDITIONS OF

KIMPTON'S ESSENTIAL SERIES.

ARRANGED IN QUESTION AND ANSWER FORM.

THE LATEST, CHEAPEST AND BEST

ILLUSTRATED SERIES OF COMPENDS EVER ISSUED.

THE ADVANTAGES OF QUESTIONS AND ANSWERS.—The usefulness of arranging the subject in the form of **Questions and Answers** will be apparent, since the student, in reading the standard works, often is at a loss to discover the important points to be remembered, and is equally puzzled when he attempts to formulate his ideas as to the manner in which the **Questions could be put in the Examination-Room.**

Essentials of Physiology. By H. A. HARE, M.D., Prof. Therapeutics in Jefferson Med. College, Philadelphia. Numerous illustrations. Fourth edition, revised and enlarged, containing a series of handsome plate illustrations taken from the celebrated "Icomes Nervorum Capitis" of Arnold. 192 pages. Cloth 4s. net.

Essentials of Diagnosis. By SOLOMON SOLIS COHEN, M.D., Prof. of Clin. Med. in the Philadelphia Polyclinic; and AUGUSTUS A. ESHNER, M.D., Instructor in Clin. Med. in Jefferson Med. Coll. Second edition, revised and enlarged. 419 pages. 60 illustrations, some of which are coloured, and a frontispiece. 6s. net.

Essentials of Obstetrics. By EASTERLY ASHTON, M.D., Obstetrician to Philadelphia Hospital. 75 illustrations. Fourth edition, thoroughly revised and enlarged. 256 pages. Cloth, 4s. net.

Essentials of Gynæcology. By EDWIN B. CRAIGIN, M.D., Gynæcologist to Roosevelt Hosp., New York. 200 pages. 62 fine illustrations. Fourth edition, revised. Cloth, 4s. net.

22200098771

e **Syphilodermata.** By
ect. on Dermatology in
and enlarged, with 72
6 pages. Cloth, 4s. net.

., Professor of Histology
, Tennessee. 255 pages,

Med
K43839

raction and Diseases of the Eye. By EDWARD , M.D., Prof. Dis. of Eye in the Philadelphia Polyclinic. New edition. In preparation.

Essentials of Diseases of the Nose and Throat. By E. BALDWIN GLEASON, M.D., Surg. to Nose, Throat, and Ear Dept., Northern Dispensary, Philadelphia. New edition. In preparation.

Essentials of Genito-Urinary and Venereal Diseases: A Manual for Students and Practitioners. By CHARLES H. CHETWOOD, M.D., Visiting Surgeon Denilt Dispensary, Depart. of Surgery and Genito-Urinary Diseases, New York. 178 pages. Illustrated. Price 4s. net.

Essentials of Diseases of Children. By WILLIAM M. POWELL, M.D. Third edition. 222 pages. Cloth, 4s. net.

Essentials of Medical Electricity. By D. D. STEWART, M.D., Chief of Neurological Clinic in the Jefferson Med. Coll.; and E. S. LAWRENCE, M.D. 65 illustrations. Cloth, 4s. net.

Essentials of Practice of Medicine. By HENRY MORRIS, M.D., late Demonstrator, Jefferson Med. Coll., Philadelphia. Numerous illustrations and a coloured frontispiece. Third edition. Cloth, 6s. net.

Essentials of Surgery. By EDWARD MARTIN, A.M., M.D., Clin. Prof. of Genito-Urinary Dis., Instructor in Operative Surg., and Lect. on Minor Surg., Univ. of Pennsylvania. Illustrated. Seventh edition, revised and enlarged. 342 pages. Cloth, 4s. net.

Essentials of Pathology and Morbid Anatomy. By C. E. ARMAND SEMPLE, B.A., M.B., Phys. to the Bloomsbury Dispensary, etc. 160 pages, 46 illustrations. Cloth, 3s. 6d. net.

Essentials of Forensic Medicine, Toxicology, and Hygiene. By C. E. ARMAND SEMPLE, B.A., M.B. 196 pages, 130 illustrations. Cloth, 4s. 6d. net.

Essentials of Bacteriology. By M. V. BALL, M.D., Bacteriologist to St. Agnes' Hospital, Philadelphia. Third edition, revised, with 81 illustrations, some in colours, and 5 plates. 218 pages. Cloth, 4s. net.

Essentials of Nervous Diseases and Insanity. By JOHN C. SHAW, M.D., Clin. Prof. of the Dis. of the Mind and Nervous System, Long Island Coll. Hosp., Med. School. 48 original illustrations. Second edition. Cloth, 4s. net.

Essentials of Diseases of the Ear. By E. B. GLEASON, S.B., M.D., Clin. Prof. of Otology. Philadelphia Med. Coll. Second edition, revised and enlarged. 206 pages, fully illustrated. Cloth, 4s. net.

Essentials of Anatomy. By FRED. J. BROCKWAY, M.D., Assistant Demonstrator of Anatomy, Coll. of Phys. and Surg., New York; and A. O'MALLEY, M.D., Instructor in Surg., New York Polyclinic. Second edition, with full-page plates. 376 pages. Cloth, 6s. net.

LONDON: HENRY KIMPTON, 13, Furnival Street, E.C.

ESSENTIALS OF
GYNECOLOGY

ARRANGED IN THE FORM OF

QUESTIONS AND ANSWERS

PREPARED ESPECIALLY FOR STUDENTS OF MEDICINE

BY

EDWIN B. CRAGIN, M.D.

Professor of Obstetrics, College of Physicians and Surgeons, New York; Attending Physician to the Sloane Maternity Hospital; Consulting Gynecologist to the New York Infirmary for Women and Children; Consulting Obstetric Surgeon, Maternity Hospital; Fellow of the American Gynecological Society, the New York Obstetrical Society, the New York Academy of Medicine, etc.

FIFTH EDITION, THOROUGHLY REVISED

BY

FRANK S. MATHEWS, M.D.

Assistant Surgeon and Pathologist, St. Mary's Free Hospital for Children; Attending Gynecologist, Roosevelt Hospital, Out-Patient Department; Assistant Pathologist, Woman's Hospital, State of New York

WITH 57 ILLUSTRATIONS

LONDON:
HENRY KIMPTON,
13, FURNIVAL ST., E. C.
1901.

Printed in America.

29821834

WELLCOME INSTITUTE
LIBRARY

Coll.	welMOmec
Call No.	WP

PREFACE TO FIFTH EDITION.

ADVANCES in Gynecology since the last edition of this work again demand its revision. It is believed that the changes and additions embodied will render the book more than ever acceptable to those for whom it is intended.

E. B. C.

PREFACE TO FIRST EDITION.

No one appreciates more fully than the Author the inadequacy of this little work for a thorough study of Gynæcology. This has not been the aim. He only hopes that as a means of review and as a summary of the results of more extensive reading, the student may find the work of some value. The Author wishes also to state that in its compilation he has freely consulted, and made use of, the standard works of Hart and Barbour, Thomas, Schroeder, The American System of Gynæcology, notes on the lectures of Prof. Geo. M. Tuttle at the College of Physicians and Surgeons, New York, and numerous journals.

E. B. C.

CONTENTS.

PAGE

Mons Veneris, ... 17
Labia Majora, ... 17
Labia Minora, ... 18
Clitoris, ... 18
Vestibule, ... 20
Fourchette, ... 20
Fossa Navicularis, ... 20
Bulbs of the Vestibule, ... 20
Vulvo-vaginal Glands, ... 21
Hymen, ... 21
Vagina, ... 21
Vaginal Secretion, ... 22
Uterus, ... 23
Mucous Membrane of Uterus, ... 25
Fallopian Tubes, ... 31
Ovaries, ... 32
Parovarium, ... 35
Urinary Tract, ... 35
Bladder, ... 36
Rectum, ... 38
Pelvic Floor, ... 40
Perineal Body, ... 41
Muscles of the Perineum, ... 42
Ischio-rectal Fossa, ... 42
Development of Pelvic Organs, ... 43
Physical Examination of Pelvic Organs, ... 43
Vaginal Examination, ... 44
Bimanual Examination, ... 46
Rectal Examination, ... 47
Instruments, ... 48
Specula, ... 48
The Sims Speculum, ... 49
The Simon's Speculum, ... 51

PAGE
Instruments, the Fergusson Speculum, ... 51
The Brewer Speculum, ... 52
Volsella, ... 54
Uterine Sound, ... 55
Uterine Probe, ... 59
Uterine Applicators, ... 59
Dilators, ... 59
Tents, ... 59
Graduated Hard Dilators, ... 61
Elastic Dilators, ... 63
Stem Pessaries 63
The Curette, ... 64
Vulvitis, ... 65
Acute Simple Catarrhal, ... 65
Chronic Catarrhal, ... 66
Gonorrhœal, ... 66
Phlegmonous, ... 68
Croupous, ... 69
Gangrenous, ... 69
Follicular, ... 70
Cyst and Abscess of Vulvo-vaginal Gland, ... 71
Pudendal Hernia, ... 72
Pudendal Hæmatocele, ... 73
Hemorrhage from Vulva, ... 74
Skin Diseases of the Vulva, ... 75
Erythema of the Vulva, ... 75
Eczema of the Vulva, ... 75
New Growths of the Vulva, ... 77
Simple Papillomata, ... 77
Pointed Condylomata, ... 77
Syphilitic Condylomata, ... 78
Pruritus Vulvæ, ... 78
Hyperæsthesia of the Vulva, ... 80
Vaginismus, ... 80
Coccygodynia, ... 81
Irritable Urethral Caruncle, ... 82
Prolapse of Urethral Mucous Membrane, ... 83
Malformations of the Vulva, ... 83

PAGE
Diseases of the Vagina, ... 84
Bacteria of the Vagina, ... 84
Simple Catarrhal Vaginitis, ... 84
Gonorrhœal Vaginitis, ... 86
Ulcerative Vaginitis, ... 86
Croupous Vaginitis, ... 87
Pelvic Peritoneum, ... 87
Pelvic Peritonitis, ... 88
Pelvic Cellulitis, ... 91
Pelvic Hæmatocele and Hæmatoma, ... 94
Menstruation, ... 98
Disorders of Menstruation, ... 99
Amenorrhœa, ... 99
Vicarious Menstruation, ... 100
Menorrhagia and Metrorrhagia, ... 101
Dysmenorrhœa, ... 102
Obstructive, ... 102
Congestive, ... 103
Neuralgic, ... 104
Ovarian, ... 104
Membranous, ... 105
Malformations of the Vagina, ... 106
Atresia of the Vagina, ... 107
Stenosis of the Vagina, ... 108
Malformations of the Uterus, ... 108
Displacements of the Uterus, ... 113
Anteversion, ... 113
Anteflexion, ... 114
Retroversion and Retroflexion, ... 116
Pessaries, ... 121
Alexander's Operation, ... 124
Hysterorrhaphy, ... 126
Prolapsus Uteri, ... 127
Laceration of Perineum and Relaxation of Vaginal Outlet, . . . 130
Hegar's Operation, ... 131
Emmet's Operation, ... 133
Saenger-Tait Operation, ... 134
Cleveland's Operation, ... 137
Hypertrophy of the Cervix, ... 140

PAGE
Stenosis of the Cervix, ... 142
Laceration of the Cervix, ... 142
Trachelorrhaphy, ... 145
Endometritis, ... 147
Acute, ... 147
Chronic 148
Metritis, ... 153
Metritis, Acute Metritis, ... 153
Chronic Metritis, ... 154
Atrophy of the Uterus, ... 156
Fibroid Tumors of the Uterus, ... 157
Inversion of the Uterus, ... 166
Polypi, ... 171
Carcinoma Uteri, ... 175
Vaginal Hysterectomy, ... 177
Sarcoma of the Uterus, ... 178
Deciduoma Malignum, ... 179
Salpingitis, ... 180
Tubercular Salpingitis, ... 183
Affections of the Ovaries, ... 184
Hemorrhage into the Ovaries, ... 184
Ovaritis, ... 184
Prolapse of the Ovary, ... 188
Tumors of the Ovary, ... 188
Cysts of the Ovary, ... 189
Parovarian Cysts, ... 194
Preparation of Catgut, ... 198
Ectopic Gestation, ... 199
Fistulæ, ... 202
Recto-vaginal Fistula, ... 204

ESSENTIALS OF GYNÆCOLOGY.

What is included in the term external genitals?

That portion of the genital tract which is visible when the patient is in the dorsal position, with knees elevated and the labia separated with the fingers, viz. : Mons Veneris, Labia Majora, Labia Minora, Clitoris, Vestibule, Fourchette and Fossa Navicularis.

What other terms are in common use for the external genitals?

Pudendum and Vulva.

The term vulva is inexact, as it originally applied to the labia, nevertheless it is in common use.

What comprise the internal organs of generation?

The Uterus, Fallopian tubes and Ovaries.

The Vagina connects the external with the internal generative organs.

Budin regards the Hymen as anatomically a folding in of the vaginal walls.

Mons Veneris.

Describe.

The Mons Veneris is a triangular projection, or cushion of adipose tissue, situated over the symphysis pubis. Anatomically, in addition to adipose tissue, it contains fibrous and elastic tissue. After puberty it is covered with hair, which has a tendency to curl, and is usually somewhat darker than the hair of the head. Numerous sebaceous and sweat glands are present.

Labia Majora.

Describe them.

The labia majora are two folds of skin which extend from the mons veneris in front to meet in the fourchette posteriorly; they

are covered externally with coarse hair, and richly supplied with sebaceous and sweat glands; they also contain adipose, fibrous and elastic tissue. Above, the round ligament can be traced into them on either side; also the remains of the canal of Nuck, which sometimes continues pervious and admits of hernia. The inner surface of the labia is smooth, and somewhat resembles mucous membrane, a few fine hairs, however, are visible on close inspection.

The labia majora in the virgin lie in contact; in old women they become atrophied and allow the labia minora to protrude.

The arterial supply is the superficial perineal branch of the internal pudic and the superficial external pudic. The veins communicate with the bulbs of the vagina and take the course of the arteries. The lymphatics empty into the inguinal glands. The nerve supply is from the superficial perineal branches of the internal pudic, the ilio-inguinal, and the genito-crural.

Labia Minora.

Describe.

The labia minora, or nymphæ, are two folds of muco-cutaneous tissue which arise about the middle of the labia majora on their inner surfaces, and extending upward divide into two portions; the two lower uniting just below the clitoris to form the frænum, the two upper just above the clitoris to form the prepuce. The venous supply is rich; it communicates with the bulbs of the vagina and with the pudic and perineal veins. The arterial supply, nerves and lymphatics are the same as for the labia majora. The sebaceous glands are very abundant.

Clitoris.

Describe.

The clitoris, the analogue of the penis in the male, is situated at the apex of the vestibule; it consists of a glans, a body and two crura.

The glans, the only part visible, is a mass of erectile tissue, about the size of a small pea, very abundantly supplied with nerves and partially covered by its prepuce.

The body also consists of erectile tissue; it is about an inch long, surrounded by a firm fibrous covering, and shown, on section, to

consist of two halves, corpora cavernosa, separated by an imperfect septum.

The crura are two prolongations of erectile tissue with a dense fibrous sheath; they arise from the anterior borders and inner surfaces of the pubic and ischiatic rami, and extend forward to unite in the body just beneath the pubic arch.

Give the vascular supply of the clitoris.

The arterial supply is from the two terminal branches of the internal pudic. The blood is returned by the dorsal vein which empties into the vesical plexus.

Describe the lymphatics of the clitoris.

The clitoris is surrounded by a plexus of lymphatics which terminate in the inguinal glands.

Describe the nerve supply of the clitoris.

The clitoris receives numerous filaments both from the sympathetic system and from the pudic nerve.

According to Savage, "small as this organ is compared with the penis, it has in proportion four or five times the nervous supply of the latter."

What are the differences between the clitoris and the penis?

The clitoris has neither corpus spongiosum nor urethra, both of which are present in the penis.

What are the points of resemblance between the clitoris and the penis?

They are both erectile.

They each consist of a glans, a body and two crura.

They each have two corpora cavernosa separated by an incomplete septum. The glans in each is partly covered by a prepuce, with its frænum attached below.

What do we find in the female as the analogue of the corpus spongiosum in the male?

The bulbs of the vestibule and the labia minora, which, in the female, lie at the side of the urethra, correspond to the corpus spongiosum in the male.

What in the male is the analogue of the labia majora in the female?

The scrotum.

Vestibule.

Describe.

The vestibule is a triangular area covered with mucous membrane, in the base of which is situated the meatus urinarius; the apex lies just below the clitoris; the sides are formed by the inner edges of the labia minora, the base by the upper margin of the vaginal orifice. Beneath the mucous membrane lies a venous plexus called the pars intermedia. The vestibule differs from the labia and mons veneris in having no sebaceous glands.

Fourchette.

Describe.

The fourchette, or posterior commissure, is a mere fold of skin formed by the junction of the labia majora at the anterior edge of the perineum.

Fossa Navicularis.

Describe.

The fossa navicularis is a boat-shaped cavity which is formed between the lower portion of the hymen and the inner aspect of the fourchette, when the latter is pulled down with the finger, or the labia are separated.

When the parts are at rest, no such hollow exists.

Bulbs of the Vestibule.

Describe them.

The bulbs of the vestibule are two oval masses of erectile tissue situated on either side of the ostium vaginæ and base of the vestibule; posteriorly, they lie in contact with the anterior layer of the triangular ligament; they are partially covered in front by the bulbo-cavernosi muscles; they extend as high as the meatus urinarius, and are connected by the pars intermedia with the cavernous tissue of the clitoris. Their size varies greatly from that of a bean, as given by Hart and Barbour, to a mass an inch and a half long.

Vulvo-Vaginal Glands.

Describe.

The vulvo-vaginal, or Bartholinian glands are small oval bodies about the size of an almond, lying just behind the lower extremities of the bulbs; they lie between the layers of the triangular ligament, and each gland has a duct about half an inch in length which opens just in front of the hymen on each side.

They secrete a glairy mucus which lubricates the parts.

Hymen.

Describe.

The hymen is a fold of mucous membrane which surrounds the ostium vaginæ; it has a connective tissue framework, and contains blood-vessels and nerves, and has a squamous epithelium covering.

From its histology and embryology, it is a fold of the vaginal wall.

The hymen may be of several forms; the most common being the crescentic. Other forms are the annular, making a ring about the ostium; the cribriform, perforated by numerous small holes; and the fimbriated, with a fringed edge. It is sometimes imperforate, a pathological condition.

What value has the hymen as a criterion of chastity?

Very slight, as neither is its absence proof that intercourse has taken place, nor is its presence an absolute proof to the contrary.

What are the carunculæ myrtiformes?

In women who have borne children there are found papillary elevations surrounding the vaginal orifice. These are the remains of the hymen, and are called carunculæ myrtiformes.

Vagina.

Describe.

The vagina is spoken of by Hart and Barbour as "a mucous slit in the pelvic floor;" it is the canal connecting the uterus and the vulva, lying between the bladder and urethra in front and the rectum behind; its walls, which are anterior and posterior, are normally in contact.

The anterior wall measures 2–2½ inches in length, the posterior 3–3½ inches. The anterior wall is shorter than the posterior, from the fact that the uterus is set into the anterior wall.

The vagina is very dilatable, and when distended is conical in shape, being much more roomy above than below.

The vaginal walls on section are seen to consist of three layers: 1, mucous; 2, muscular; 3, connective tissue.

The mucous membrane on both anterior and posterior walls presents at the lower portion of the canal numerous ridges or rugæ, extending transversely from a central column; the anterior being the more distinct. The epithelium covering the mucous membrane is of the squamous variety. The vaginal mucous membrane normally contains no glands.

The muscular coat consists of two layers of unstriped muscle, the outer longitudinal one being well developed, the inner circular one being poorly developed except at the orifice.

The outer coat is of connective tissue, and contains the external plexus of veins.

The roof, or fornix of the vagina, that portion of the canal surrounding the cervix, is, for convenience, divided into four portions: the anterior fornix, the posterior fornix, and the lateral fornices; of these the posterior is the deepest.

Describe the vaginal secretion.

It is a rather scant, white, opaque, curdy material, made up of exfoliated cells of the vaginal mucous membrane and some exudate from the blood-vessels. It contains mucus only from admixture with the cervical secretion. It has a decided acid reaction due to lactic acid, resulting from the action of the many saprophytic bacteria normally found in the vagina.

What is the arterial supply of the vagina?

The arterial supply is from the vaginal arteries, which supply the lateral walls; branches of the uterine arteries supplying the upper portion, and branches of the pudendal arteries the lower. These anastomose with each other and with the vesical and rectal arteries.

Describe the veins of the vagina.

The vaginal veins form plexuses which surround the canal like

sheaths; one being external to the muscular layer, the other just beneath the mucous membrane.

"These communicate freely with the pudendal, vesical and hemorrhoidal plexuses below, and with the plexuses of the broad ligament above." These veins contain no valves.

Describe the lymphatics of the vagina.

The lymphatics of the lower fourth of the vagina, together with those from the external genitals enter the inguinal glands.

The lymphatics from the upper three-fourths of the vagina join with those from the cervix and bladder, and enter the iliac glands.

According to Poirier, some of them enter a gland at the side of the cervix in the base of the broad ligament.

Describe the nerve supply of the vagina.

The vagina is supplied by branches of the inferior hypogastric plexuses of the sympathetic system. These plexuses lie on either side of the vagina.

Give the relations of the vagina.

The anterior vaginal wall is connected in its lower half with the urethra, in its upper half with the neck and fundus of the bladder; the former connection is much more intimate than the latter. The posterior vaginal wall in its lower fourth lies in connection with the perineal body, in its middle two-fourths with the rectum, in its upper fourth with the cul-de-sac of Douglas. The anterior fornix is distant $1\frac{1}{2}$ inches from the utero-vesical pouch, and through this fornix can normally be felt the body of the uterus and the angle it makes with the cervix.

The posterior fornix is in contact with the cul-de-sac of Douglas. The lateral fornices are in relation with the bases of the broad ligaments, and through these fornices can normally be felt the vessels of the broad ligament, and occasionally the ovary and tube of that side.

The vagina makes an angle of 60° with the horizon when the woman is erect.

Uterus.

Give the gross anatomy.

The uterus, the organ of gestation, is a hollow, pear-shaped organ, flattened antero-posteriorly, situated in the pelvis between the bladder

and rectum. It measures in the virgin about 3 inches in length, 2 inches in breadth, at the level of the Fallopian tubes, and one inch in thickness. The weight of the virgin uterus varies from 1 to $1\frac{1}{2}$ oz.

It consists of three portions: the cervix, body and fundus.

As viewed externally, the uterus, on its anterior surface, is nearly flat, its posterior surface convex; a little below the centre is a slight constriction called the isthmus.

The cervix is that portion of the uterus below the isthmus, and which projects in part into the vagina.

FIG. 1.

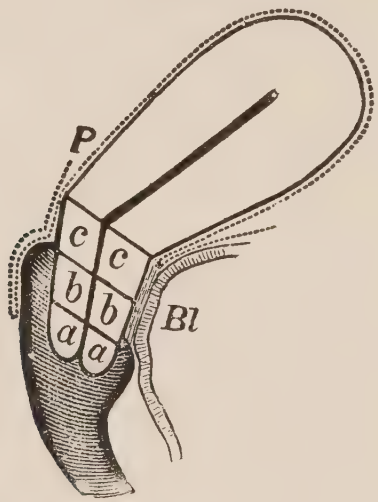

Diagram of Uterus, to show divisions of Cervix. (*Schroeder.*)
a, Infra-vaginal portion; *b*, Intermediate portion; *c*, Supra-vaginal portion; *Bl*, Bladder; *P*, Peritoneum. The dotted line shows peritoneum.

The body is that portion between the isthmus and the line joining the entrance of the Fallopian tubes.

The fundus is the portion above this line.

Describe the uterine canal.

The uterine canal measures normally $2\frac{1}{2}$ inches, and holds about 12 drops; the cervical portion of the canal is spindle-shaped; the remainder is triangular, with anterior and posterior walls in contact.

What are the openings into the uterine cavity?

There are three: the os externum, which communicates with the vagina; and the orifices of the Fallopian tubes at the upper angles,

which connect the uterine with the peritoneal cavity. The os internum connects the cavity of the cervix with that of the body.

What divisions of the cervix are made?

Schroeder divides the cervix into three portions, as seen from the accompanying figure, (Fig. 1, *a*, *b*, *c*).

a. The infra-vaginal portion.
b. The intermediate portion.
c. The supra-vaginal portion.

The infra-vaginal portion of the cervix (*a*) is that below the level of the attachment of the anterior vaginal wall.

The supra-vaginal portion (*c*) is that above the level of the attachment of the posterior vaginal wall.

The intermediate portion (*b*) is that between the infra- and supra-vaginal portions.

What portions of the cervix project into the vagina?

The infra-vaginal portion of the anterior lip, and the infra-vaginal and intermediate portions of the posterior lip.

For practical purposes, it is sufficient to divide the cervix into the supra-vaginal portion, that above the attachment of the vagina; and the infra-vaginal, that within the vagina.

What are the three elements in the structure of the uterus?

1. The mucous membrane.
2. The muscular coat.
3. The peritoneal coat.

Mucous Membrane of the Uterus.

Describe that of the cervix.

The mucous lining of the cervix differs from that of the body of the uterus. In the cervix it is thrown into folds presenting the arbor vitæ appearance, there being a central ridge on both anterior and posterior walls, and from these ridges secondary ridges extending obliquely.

The anterior and posterior ridges are not directly opposite, but fit past one another. The epithelium is ciliated on the ridges, non-ciliated in the depressions (de Sinéty).

The mucous membrane of the cervix is rather sparingly supplied with rather simple racemose glands whose secretion is mucous.

The mucous membrane covering the vaginal portion of the cervix closely resembles that of the vagina, consisting of vascular papillæ covered by squamous epithelium.

Describe the mucous membrane of the body of the uterus.

The mucous lining of the body of the uterus is smooth, velvety and of a grayish red color; it is directly connected with the muscular coat, with no submucous layer. It averages about $\frac{1}{25}$ of an inch in thickness, and consists of columnar, ciliated epithelium, on a base of connective tissue between whose fibres numerous lymph spaces are found. The mucous membrane is thickly studded with glands, the utricular glands, which penetrate the whole thickness of the mucous layer. These glands are of the tubular variety, and are frequently bifurcated at their blind extremities. They are lined with prismatic ciliated epithelium, resting on a thin membrana propria. Their direction is not at right angles to the surface, but, according to Turner, more or less oblique. Their secretion is a serous one.

To what changes is the normal uterine mucosa subject?

1. That of the child is destitute of glands. These make their appearance a few years before puberty.

2. Preceding each menstrual flow the cells of the stroma become swollen, the superficial capillaries dilated, and finally there is an exudation of plasma and diapedesis of red cells under the epithelium.

3. Should pregnancy occur, the stroma cells become much larger and polygonal, glands disappear from the surface of the mucosa, and are only seen as distorted and cystic ones in the deep layer. Thus altered the mucosa becomes the "decidua."

4. After the menopause the mucosa atrophies and nearly all glands disappear.

Describe the muscular structure of the uterus.

The muscular structure of the uterus is most marked after impregnation; it can then be separated into three layers:—

1. The external or longitudinal.
2. The middle or oblique.
3. The internal or circular.

The external layer is most distinct on the anterior and posterior surfaces, where it is seen to consist of fibres running up longitudinally over the fundus; it sends fibres into the broad, round, ovarian and utero-sacral ligaments and also into the Fallopian tubes.

The middle, or oblique layer has no regular arrangement; some of the fibres run longitudinally, some transversely and some obliquely; they surround the blood vessels, and on this account this layer is of great importance; it constitutes the chief portion of the uterine wall.

The internal or circular layer shows fibres arranged in a circular manner, most distinct around the orifices of the Fallopian tubes and at the os internum.

Describe the peritoneal coat of the uterus.

The peritoneum covers the anterior surface of the uterus above the level of the internal os; it extends over the fundus, covers its posterior surface as low as the attachment of the posterior vaginal wall, and extends down the latter for about an inch.

Describe the arterial supply of the uterus.

The uterus is supplied by the uterine and ovarian arteries, as seen by the accompanying figure. (Fig. 2.)

The uterine artery arises from the anterior division of the internal iliac, runs between the folds of the broad ligament to about the level of the os externum, and then turns upward along the side of the uterus to unite with the descending branch of the ovarian artery; it gives off numerous lateral branches to the uterus, anastomosing with those of the opposite side; these are very tortuous and are called the "curling arteries of the uterus."

Sometimes the vaginal artery springs directly from the uterine.

Opposite the internal os, the uterine artery gives off a branch which, uniting with its fellow of the opposite side, surrounds the cervix and is called "the circular artery."

The ovarian artery arises directly from the aorta, runs between the folds of the broad ligament, at its upper part, to the upper angle of the uterus; it gives off a few large vessels to the outer extremity of the tube, and then a number of very tortuous vessels which surround the ovary.

Just before reaching the uterus, it gives off a number of branches

to the proximal extremity of the tube and one to the round ligament.

At the angle of the uterus it divides into two branches; one sup-

FIG. 2.

Distribution of ovarian, uterine and vaginal arteries (*Hyrtl*).
a, ovarian artery; *a'* and *b'*, branches to tube; *c'*, branches to ovary; *b*, branch to round ligament; *c*, branch to fundus; *d*, branch to join uterine artery; *e*, uterine artery; *f*, anterior branch of internal iliac; *g*, vaginal arteries; *h*, azygos artery of vagina.

plies the fundus and anastomoses with its fellow of the opposite side; the other descends along the side of the uterus and anastomoses with the uterine artery.

The tortuosity and free anastomoses across the median line are noticeable features of the arteries of the uterus.

Describe the venous supply of the uterus.

The uterus is surrounded beneath the peritoneum by a plexus of veins, called the uterine plexus; this receives the blood from the uterine walls and communicates with the vaginal and vesical plexuses below and the pampiniform above; it empties into the internal iliac and ovarian veins.

Describe the lymphatics of the uterus.

The lymphatics from the body of the uterus join with those from the ovary and tube and terminate in the lumbar glands.

The lymphatics from the cervix pass beneath the base of the broad ligaments to the iliac glands.

The lymphatics of the uterine cornu follow the round ligament and terminate in the inguinal glands.

Give the nerve supply of the uterus.

The chief nerve supply of the uterus is from the inferior hypogastric plexus of the sympathetic.

The cervix also receives branches from the upper sacral nerves.

What is the normal position of the uterus?

This question has been frequently discussed and at great length.

It is now sufficient for practical purposes to say that the uterus, when the pelvic organs are normal and when bladder and rectum are empty, lies slightly anteflexed and slightly anteverted; but the position is constantly changing with the degree of distention of the bladder and rectum, especially the former.

What are the ligaments of the uterus?

There are two utero-vesical ligaments, two round, two broad and two utero-sacral.

Describe the utero-vesical ligaments.

They are two folds of peritoneum passing between the bladder and the lower portion of the uterus on each side.

Describe the round ligaments.

They are two musculo-fibrous cords, 4–5 inches in length, which extend from the superior angles of the uterus, in the anterior folds of the broad ligaments and below the Fallopian tubes, forward and outward to the inguinal canal; thence through this canal where they terminate in three points of insertion: the external, middle and internal. The external blends with the outer pillar of the ring near Gimbernat's ligament. The middle terminates in the upper portion of the external ring. The internal unites with the conjoined tendon. Besides muscular and fibrous tissue, these ligaments contain areolar tissue, vessels and nerves.

They are of importance surgically as being those shortened in operations for the correction of posterior displacements.

Describe the broad ligaments.

They are two folds of peritoneum which extend from the sides of the uterus to the wall of the pelvis, "along a line which is situated between the great sacro-sciatic notch and the margin of the obturator foramen as far down as the level of the ischial spine." The greater part of its superior border, on each side, is occupied by the Fallopian tube; the part of the superior border not so occupied is called the infundibulo-pelvic ligament.

What is the "mesosalpinx"?

It is that portion of the broad ligament lying between the tube, ovary, and ovarian ligament.

What two folds are made in the broad ligament in addition to that occupied by the Fallopian tube?

An anterior fold caused by the round ligament and a posterior fold caused by the ovarian ligament.

Describe the ovarian ligament.

It is a fibro-muscular cord about an inch in length, which connects the ovary with the side of the uterus, just below the entrance of the Fallopian tube. It lies in, and is surrounded by, the posterior fold of the broad ligament.

What are contained between the folds of the broad ligament on either side?

The round ligament, Fallopian tube, ovarian ligament, the paro-

varium, cellular tissue, uterine and ovarian arteries, the pampiniform plexus and other veins, numerous lymphatics and nerves.

When the broad ligament is held tense the ovary appears as if stuck on its posterior surface.

Describe the utero-sacral ligaments.

They are folds of peritoneum containing muscular and cellular tissue, which extend from the sides of the uterus, at the level of the internal os, backward and outward to the second sacral vertebra.

What is the meaning of the term "uterine appendages," as usually employed?

The Fallopian tubes and ovaries.

Fallopian Tubes.

Describe them.

They are two tubes 3–5 inches in length, which extend laterally from the superior angles of the uterus; they lie within the folds of the broad ligaments, and their direction is first outward, then forward, backward and inward toward the ovary.

They are divided for consideration into three portions: the isthmus, the ampulla and the fimbriated extremity.

The isthmus is the narrowest portion; it measures about an inch in length, and extends from the angle of the uterus directly outward, joining the ampulla; its lumen is only large enough to admit a fine bristle.

The ampulla is the curved, dilated portion of the tube; its lumen admitting an ordinary uterine sound.

The fimbriated extremity (infundibulum) is the expanded, funnel-shaped outer end, which is surrounded by fringe-like processes (fimbriæ), both primary and secondary, the latter arising from the former, which are 4–5 in number. The longest of the primary fimbriæ lies to the inner side, is grooved, and is attached to the ovary; this is called the fimbria ovarica.

The tubes, on section, are seen to consist of four layers or coats; the peritoneal coat; two muscular coats, the outer being longitudinal, the inner circular; and a mucous coat.

There is no submucous layer.

The mucous membrane is thrown into longitudinal folds; the epithelium is columnar and ciliated.

Give the arterial supply of the Fallopian tubes.

The Fallopian tubes are supplied by the ovarian arteries, which send branches directly to the outer and inner portions of the tube and supply the middle third through branches from the plexus about the ovary.

Describe the veins, lymphatics and nerve supply of the Fallopian tubes.

The veins of the tubes enter the pampiniform plexus on either side.

The lymphatics join with those from the upper part of the uterus and from the ovary, and terminate in the lumbar glands.

The nerve supply is from the inferior hypogastric plexuses.

What is the direction of the current due to motion of the ciliæ of the epithelium in the uterus and tubes?

The ciliæ have such a motion as to propel fluids outward, *i. e.*, in the tube toward the uterus, and in the uterus toward the vagina.

Ovaries.

Give their gross anatomy.

The ovaries are two "flattened ovoid" bodies lying in the plane of the brim of the pelvis, on either side of the uterus, and appear as elevations on the posterior surface of the broad ligament. They are situated below the outer extremities of the tubes.

They present for consideration two borders, an anterior and posterior; two surfaces, a superior and an inferior; and two extremities, an outer and an inner.

The anterior border is nearly straight; the posterior is convex.

The anterior border is called the hilum, and serves for the entrance of blood vessels and nerves.

The superior surface is nearly flat; the inferior is convex.

The outer extremity is broad and convex; the inner is narrow and tapers into the ovarian ligament.

An ovary averages about $1\frac{1}{2}$ inches in length, $\frac{3}{4}$ of an inch in breadth and $\frac{1}{2}$ an inch in thickness; it weighs about 87 grains.

Give the minute anatomy of the ovary.

The ovary, on section, is seen to consist of a medullary and cortical portion; the former being more vascular and of a softer consistency than the latter. The microscope shows connective tissue, numerous Graafian follicles scattered through the cortex, blood vessels, lymphatics, nerves and unstriped muscular fibres.

At the base or attachment of the ovary to the broad ligament can be seen a white line which marks the transition from the flat cells of peritoneum to the cuboidal ones, the "germinal epithelium" covering the surface of the ovary. The origin of both sorts of cells is the same. Both are derived from the mesothelial cells of the mesoblast, and later become differently modified to fit them to fulfil their very dissimilar functions.

The layer of "germinal epithelium" rests on a thin, dense musculo-fibrous layer, called the tunica albuginea.

The Graafian follicles are small vesicular bodies, more numerous and smaller in the superficial zone of the cortex than in the deeper, with the exception of a few which have matured and approached the surface of the ovary.

Foulis estimates that at birth each human ovary contains not less than 30,000 Graafian follicles (Playfair).

Give the structure of a Graafian follicle.

On examining a Graafian follicle from without inward, we find the following structures (Fig. 3):—

The *theca folliculi*, which is divisible into an outer fibrous layer, the tunica fibrosa, and an inner vascular and cellular layer, the tunica propria; within this is the *membrana granulosa*, a layer of columnar epithelium which encloses the *liquor folliculi;* at one side there is a cellular eminence called the *discus proligerus*, which encloses the ovum. The outer covering of the ovum is the *vitelline membrane*, or *zona pellucida*, surrounding the *vitellus* or *yolk*. At one point of the latter is seen the *germinal vesicle*, and within this the *germinal spot*. A Graafian follicle measures from $\frac{1}{100}$ to $\frac{1}{20}$ inch in diameter; a germinal spot, not over $\frac{1}{3000}$ inch.

Give the arterial and venous supply of the ovaries.

The ovaries are supplied by the ovarian arteries, which arise directly from the aorta.

The veins of the ovary emerge at the hilum and enter the collection of veins called the "bulb of the ovary." This communicates with the veins from the Fallopian tube and upper portion of the

Fig. 3.

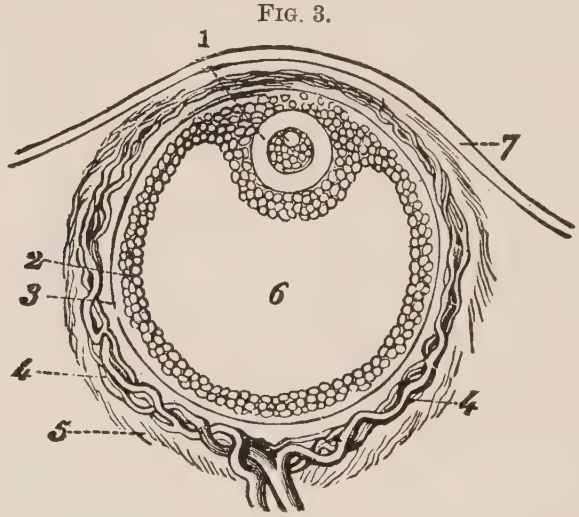

Diagrammatic Section of Graafian Follicle.

1. Ovum. 2. Membrana granulosa. 3. External membrane of Graafian follicle. 4. Its vessels. 5. Ovarian stroma. 6. Cavity of Graafian follicle. 7. External covering of ovary.

uterus, forming a collection called the pampiniform or ovarian plexus; from this springs the ovarian vein, which, on the right side, terminates in the inferior vena cava, on the left side, in the left renal vein. The left ovarian vein has no valve at its termination. Some apply the term pampiniform plexus to all the veins in the broad ligament.

Give the lymphatics and nerve supply of the ovary.

The lymphatics join with those from the tube and upper portion of the uterus and terminate in the lumbar glands. The nerve supply is from the inferior hypogastric plexus.

What is the position of the long axis of the ovary?

This question has been much discussed. The long axis of the ovary may be regarded as lying a little obliquely to the transverse

axis of the pelvis, and with a direction slightly backward. His describes the long axis as vertical, but this does not coincide with the results of autopsies where the pelvic contents have been normal.

Parovarium.

Describe it.

The parovarium, which is the remains of the Wolffian body, consists of a series of tubes situated between the folds of the broad ligament, on either side of the uterus, and lying between the ampulla of the tube and the hilum of the ovary.

One of the tubes is horizontal and runs toward the uterus; the others are nearly vertical, converging toward the hilum; they vary greatly in number, in fact, from 6 to 30.

The outer 6–10 have a well-marked lumen and are lined with ciliated epithelium; those internal to these are merely fine fibrous cords.

The horizontal tube running toward the uterus is called the duct of Gärtner. It is rarely continued down along the side of the uterus or even to the vagina. The parovarium is of pathological importance, as occasionally the seat of cysts.

What in the male corresponds to the parovarium in the female?

The epididymis.

Urinary Tract.

Describe the urethra.

The female urethra is a musculo-membranous canal about $1\frac{3}{8}$ inches in length, imbedded in the anterior vaginal wall, and extending from the vestibule to the neck of the bladder; it runs upward and backward, "parallel with the plane of the pelvic brim."

It consists of three coats; the outer two being muscular, the inner, mucous membrane.

Of the muscular coats, the outer is circular, the inner longitudinal. The mucous membrane in the lower portion of the canal is covered with squamous epithelium, while higher up the epithelium is transitional, like that of the bladder.

The meatus urinarius, the outer extremity of the urethra, is situated in the median line at the base of the vestibule.

Describe Skene's tubules.

Just within the meatus, on each side, are the openings of Skene's tubules, which he describes as lying near the floor of the urethra, just beneath the mucous membrane, and extending parallel to the canal about three-fourths of an inch. Their function is unknown.

Bladder.

Describe it.

The bladder is a hollow musculo-membranous organ, situated in the pelvis "between the symphysis pubis in front and the vagina and uterus behind."

The bladder presents for consideration a body, a base or fundus, and a neck. The body is all that portion above the lines joining the ureteric openings and the centre of the symphysis pubis.

All below these lines is the base or fundus. The portion of the fundus between the urethral and ureteric orifices is the trigone.

The constricted portion continuous with the urethra is the neck.

The wall of the bladder consists of three coats: a peritoneal, a muscular and a mucous.

The peritoneal coat is found only on the summit of the bladder and on the upper part of the posterior surface. The muscular coat consists of two layers: an outer longitudinal and an inner circular; the latter being most marked around the urethral orifice.

The mucous membrane consists of several layers of transitional epithelium resting on a membrana propria; the superficial cells are squamous. It contains no glands.

The mucous membrane is thrown into numerous folds, except at the trigone, where it is more closely connected with the underlying tissue.

The mucous membrane is supported by a submucous layer of fibrous and elastic tissue, containing blood vessels, lymphatics and nerves.

What is the arterial supply of the bladder and urethra?

The bladder receives its arterial supply from the superior, middle and inferior vesical, and from branches of the uterine and vaginal arteries.

They are all derived from the anterior division of the internal iliac.

The urethra is supplied by branches from the vaginal arteries.

What is the venous supply of the bladder and urethra?

"The veins form a complicated plexus round the neck, sides and base of the bladder." (Gray.)

This is called the vesical plexus; it lies external to the muscular coat and terminates in the internal iliac vein.

The urethra is surrounded by a venous plexus which communicates with the vaginal plexus.

Give the lymphatic and nerve supply of the bladder and urethra.

The lymphatics of the bladder and urethra empty into the iliac glands. Their nerve supply is derived from the inferior hypogastric plexuses of the sympathetic system, and from the 3d and 4th sacral nerves of the cerebro-spinal system.

What are the principal venous plexuses of the pelvis?

The vaginal plexuses.
The vesical plexus.
The hemorrhoidal plexus.
The uterine plexus.
The pampiniform, or ovarian plexus.
The bulb of the ovary.

Describe the course of the ureters in the pelvis.

The ureters cross the external iliacs just beyond the bifurcation of the common iliacs; they then pass downward and forward along the lateral walls of the pelvis, enter the broad ligaments, and run forward and inward. At the level of the internal os they are crossed in front by the uterine arteries (see Fig. 4), and are there situated about half an inch from the uterus. They pass alongside of the vagina a little way, converge still more, enter the vesico-vaginal septum, and pierce the bladder a little above the middle of the anterior vaginal wall; they are here separated two inches from each other and one-half to three-fourths of an inch from the cervix.

Rectum.

Describe.

The rectum is the lower extremity of the large intestine, about 8 inches in length, extending from near the left sacro-iliac synchrondrosis to terminate in the anus between the coccyx and perineum.

FIG. 4.

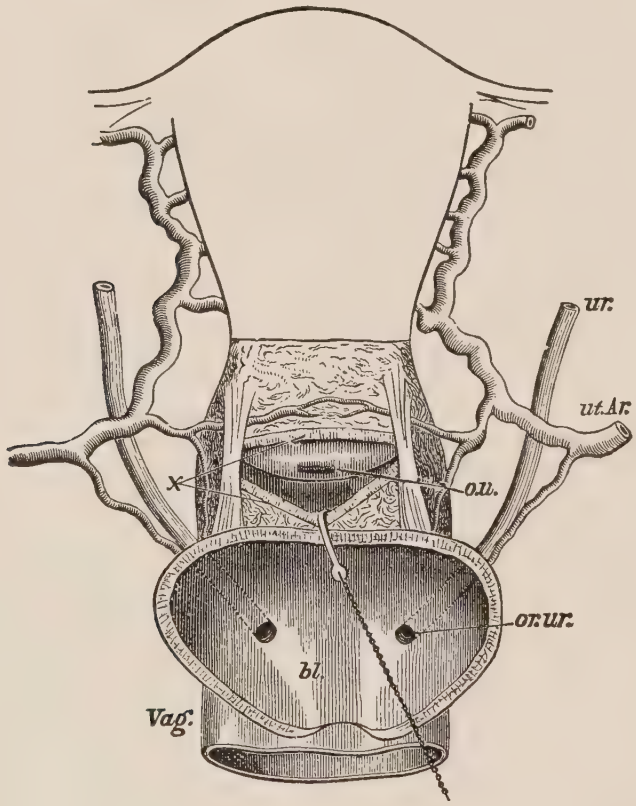

Drawing from a dissection made to show relations of ureters, uterine arteries, bladder, etc. (*J. Greig Smith.*)

ur., ureter; *ut.Ar.*, uterine artery; *ou*, os uteri exposed by an incision, *x*, made through the top of the vagina; *bl.*, bladder, the walls of which are cut down to the insertion of the ureters into its base, *Vag.*, vagina.

It presents three curves :—

1. Downward, backward and inward to the 3d sacral vertebra.
2. Forward to the apex of the perineum.
3. Backward to the anus.

The rectum is invested by peritoneum at its upper part.

It consists of a mucous and a submucous layer and two muscular layers—a longitudinal and a circular, the former being external.

The mucous membrane is covered with columnar epithelium and contains numerous follicles of Lieberkühn.

At its lower portion the mucous membrane is thrown into perpendicular folds called columns of Morgagni; the depressions between them being called the sinuses of Morgagni.

There are three oblique folds of importance, including not only the mucous and submucous layers, but part of the muscular coat.

One projects from the anterior wall 1½ inches from the anus.

Another is on the right side near the sacral promontory, and a third is situated midway between the two, on the left side.

The external orifice is guarded by the sphincter ani muscle which surrounds the canal, and is inserted into the coccyx behind and the perineum in front.

Give the vascular and nerve supply of the rectum.

The arterial supply of the rectum is from the superior, middle and inferior hemorrhoidal arteries. The veins form a plexus beneath the mucous membrane which communicates with another surrounding the exterior of the canal; from this spring veins corresponding to and accompanying the arteries.

The superior hemorrhoidal vein empties into the inferior mesenteric of the portal system.

The middle and inferior hemorrhoidal empty into the internal iliac of the general venous system.

The lymphatics terminate in the sacral glands.

The nerves are derived from the hypogastric and sacral plexuses.

Give the relations of the rectum.

At its upper portion the rectum is surrounded by peritoneum and lies in direct relation anteriorly with the cul-de-sac of Douglas.

At about 3 inches from the anus the peritoneum leaves the rectum, which then lies loosely attached to the posterior wall of the vagina for 1½ inches.

The remainder is separated from the vagina by the perineal body.

Posteriorly, the rectum is connected at its upper part by the meso-

rectum to the sacrum; at its lower part by fibrous tissue to the sacrum and coccyx.

On each side it receives the insertion of the levatores ani and is surrounded below by the sphincter ani.

Pelvic Floor.

Describe the segments of the pelvic floor.

According to Dr. Hart, the pelvic floor consists of two segments: the pubic and sacral; the *pubic* consisting of the bladder, urethra, bladder peritoneum and the anterior vaginal wall; the *sacral* comprising the rectum, perineal body and posterior vaginal wall.

According to the same authority, also, the pubic segment is made up of loose tissue, loosely attached to the pubes, and is drawn up during labor; the sacral segment is made up of dense tissue, closely attached to sacrum and coccyx, and is driven down during labor.

Describe the muscles and fascia of the pelvic floor, as dissected from above.

On examining the pelvic floor from above, we find the pelvic fascia attached laterally to the brim of the pelvis, to the spine of the ischium behind, to the lower portion of the symphysis pubis in front, and to a tendinous band—"white line"—joining the two latter points. Behind the spine of the ischium the pelvic fascia is continuous with a thin layer covering the pyriformis muscle. At the "white line" the pelvic fascia divides into the recto-vesical fascia, which covers the upper surface of the levator ani muscles, and the obturator fascia, covering the obturator muscles. The recto-vesical fascia arising from the "white line" extends downward and inward, and unites in the median line with its fellow of the opposite side. This forms a fascial diaphragm which is perforated by the rectum and vagina, to each of which it is firmly attached and furnishes a sheath from that point downward. The bladder and rectum also receive ligaments from this fascia.

On removing this fascial diaphragm, we meet with a muscular diaphragm formed by the levator ani and coccygeus muscle of each side meeting in the median line.

The coccygei arise from the ischial spines, and are attached to the sides of the lower segment of the sacrum and to the sides and anterior surface of the coccyx.

The levatores ani arise from the posterior aspect of the pubes, from the spine of the ischium and from the "white line" of the pelvic fascia connecting these points. They extend downward and inward and are attached to the vagina, the rectum, to each other and to the tip of the coccyx. This muscular diaphragm surrounds both vagina and rectum.

The under surface of this muscular diaphragm is covered by a thin layer of fascia which is attached on each side to the obturator fascia. On removing the muscular diaphragm with its upper and lower fascia, there remains, filling the pelvic outlet, the perineal body, the muscles of the perineum and the ischio-rectal fossa.

Perineal Body.

Describe.

The perineal body is a mass of muscular, fibrous and adipose tissue, somewhat pyramidal in shape, lying between the lower ends of the vagina and rectum; it measures 1½ inches in height, 1½ inches in breadth and ¾ inch antero-posteriorly. Its base is covered by skin which is sometimes wrongly spoken of as "the perineum," which should always refer to the perineal body.

The muscles which are attached to the perineal body are the bulbo-cavernosi, transversi perinei, sphincter and levatores ani.

Give the vascular and nerve supply of the perineal body.

The arterial supply of the perineal body is from the internal pudics.

The veins terminate in the pudic veins.

The lymphatics end in the inguinal glands.

The nerve supply is from the pudic nerve.

What are the functions of the perineal body?

1. To prevent vaginal rectocele.
2. To help form a compact pelvic floor.
3. To serve as a fixed point for muscular attachment.

Muscles of the Perineum.

Name and describe them.

On each side of the vaginal orifice we find three muscles: bulbo-cavernosus, ischio-cavernosus or erector clitoridis, and the transversus perinei.

The bulbo-cavernosus arises from the perineal body on each side of the vagina, with its fellow encircles the vaginal bulbs and vestibule, and divides into three slips; one going to the posterior surface of the bulb, another to the under surface of the corpus cavernosum of the clitoris, and the third to the mucous membrane of the vestibule.

The bulbo-cavernosi compress the bulbs of the vagina.

The transversus perinei arises from the ramus of the ischium and is lost in the perineal body.

The ischio-cavernosus or erector clitoridis, arises from the front of the tuberosity of the ischium and is inserted into the crus clitoridis.

These muscles are supplied by the internal pudic artery and by branches of the pudic nerve.

The veins enter the pudic veins.

The lymphatics terminate in the inguinal glands.

Ischio-rectal Fossa.

Give its gross anatomy.

It is a pyramidal-shaped area, largely filled with fat, situated on either side of the rectum; the sides are formed by the obturator internus without and the levator ani within; the base by the transversus perinei and the lower edge of the gluteus maximus.

Describe the fascia covering the pelvic floor below.

From without inward we find the superficial fascia in two layers, the external being continuous with the general superficial fascia of the body. The deep layer is attached to the border of the pubic arch in front and laterally; posteriorly, it passes around the transversus perinei muscles and is attached to the base of the anterior layer of the triangular ligament.

Beneath the perineal muscles we find the triangular ligament, consisting of two layers of fascia, the anterior and posterior, filling in the pubic arch.

Development of the Pelvic Organs.

Describe briefly.

In the latter part of the first month there appear in the fœtus, on either side of the primitive vertebræ, the Wolffian bodies, which play the part of temporary kidneys. They soon wither, and by the end of the 3d month have largely disappeared, but their remains persist, in the female, in the parovarium and Gaertner's duct. At the inner side of the Wolffian bodies there appears an invagination of the germ epithelium; this develops into the duct of Mueller, one for each Wolffian body. These coalesce below to form the uterus and vagina.

The ovary first appears as a white ridge on the inner side of the Wolffian body; this ridge being formed of connective tissue covered with germ epithelium; from the former is developed the stroma of the ovary, and from the latter are formed the Graafian follicles and ova.

Until the latter part of the second month of fœtal life the urinary, genital and intestinal canals open into a common vault—the cloaca. At about the 6th–7th week this common opening is divided into the anal opening posteriorly and the uro-genital anteriorly. This separation is completed by the formation of the perineal body at about the tenth week.

The uro-genital canal is later divided into the urethra anteriorly and the vagina posteriorly.

Physical Examination of the Female Pelvic Organs.

What are the methods of examination?

I. Non-instrumental. II. Instrumental.

I. Non-instrumental.

a. Inspection of external genitals.
b. External abdominal examination.
c. Vaginal examination.
d. Bimanual examination, with its modifications.
e. Rectal examination.

What should you notice on inspection of the external genitals?

1. Notice whether or not the vulva is the seat of venereal sores warts, abscesses, pediculi, etc.

2. Separate labia and notice condition of hymen and perineum, whether intact or lacerated; the shape of hymen if intact. If perineum lacerated, notice whether through the sphincter ani or not; notice, also, condition of urethra.

3. Tell patient to strain, and with labia still separated, notice whether anterior or posterior vaginal walls prolapse or not, thus forming cystocele or rectocele.

4. During this inspection it is well to pass the thumb and forefinger along each labium majus to ascertain whether the vulvovaginal glands or their ducts are enlarged or not.

What are the principal elements in a complete external abdominal examination?

1. Position and Preparation of patient.—Patient should be on back with knees drawn up; the abdomen should be uncovered as low down as the pubes; the latter not being exposed; bladder and rectum should be empty.

2. Inspection.—Observe the form and color; notice whether irregularities in form are present or not.

3. Palpation.—Use both hands; they should be warm; use the palms and palmar surface of fingers rather than their tips; employ very little force. If a tumor is present, notice whether it is solid or fluctuating, whether fixed or mobile; if possible, determine whether or not it is attached to one of the pelvic organs.

Notice whether it pulsates or is the seat of intermittent contractions.

Palpate inguinal regions for enlarged glands or herniæ.

4. Percussion.—Patient should be first percussed in usual manner while lying on back and then when turned on either side.

Vaginal Examination.

Describe the method of performing it.

Have the patient on back; knees drawn up; if a married woman, employ two fingers, if unmarried, use one.

Have the examining finger or fingers well lubricated and folded into the palm until you approach the vulva; then let them sweep over the perineum and fourchette between the labia till they enter the vaginal orifice. Do not pass from above downward over the clitoris. After entering the vagina pass the finger or fingers backward toward the hollow of the sacrum.

What are the contraindications to a vaginal examination?

A vaginal examination should not be made in an unmarried woman unless there are strong reasons for suspecting trouble with the pelvic organs, and then only in the presence of a relative or female friend.

It should not be made during a normal menstruation.

What is the value of a vaginal examination per se?

The value of a vaginal examination by itself is comparatively small; and it is rarely employed save as a part of a bimanual examination.

One can, however, determine the following points by a vaginal examination, and they should be carefully noted:—

The condition of perineum and vaginal orifice.

Presence or absence of Painful Spots;
Spasm;
Enlargement of vulvo-vaginal glands; etc.

Condition of vaginal walls:—
Heat;
Moisture;
Presence or absence of
Rugæ;
New growths;
Fistulæ; etc.

Projections of vaginal walls from
Fæces in rectum;
Inflammatory deposits;
Tumors in the peritoneal pouches.

Condition of cervix:—

Position;	Density;
Shape;	Mobility;
Size;	Lacerated or not.

Condition of os :—

Size ;
Shape ;
Projections through it.

Bimanual Examination.

What is the method of performing it ?

The position of the patient and the method of introducing fingers are the same as for the vaginal examination just described. As regards which hand shall be used internally, the right is usually employed first ; but to make a complete bimanual, it is best to employ internally the right hand for the right side of the pelvis, and the left hand for the left ; in this way the palmar surfaces of the internal and external fingers are approximated, and any departure from the normal, on either side, is better mapped out than when the right hand alone is used for the internal examination.

Describe the use of the external hand in the bimanual.

The ulnar surface of the external hand should be used rather than the palm ; it should be applied to the abdomen some distance above the pubes and steadily depressed toward the opposing fingers within the vagina, while the patient relaxes her abdominal muscles and breathes quietly, with mouth open.

Describe the use of the internal examining fingers in the bimanual.

While the ring and little fingers are strongly flexed into the palm and the thumb lies on the pubes or between the thighs, place the middle examining finger on the cervix and the index in the anterior fornix and raise the uterus toward the external hand. The first step for the student in acquiring skill in the bimanual is to feel, through the abdominal wall, a body which transmits motion from the external hand to the finger on the cervix. This, in a normal case, is the fundus of the uterus ; future examinations will enable one to map out more and more the shape of the fundus.

What is a good order to follow in making a bimanual examination ?

1. Determine the position of the uterus by attempting to approxi-

mate external and internal fingers ; the internal being placed first on cervix, then in anterior fornix and then in posterior; the external hand exerting counter pressure.

2. Determine condition of tubes, ovaries and parametria; using right hand internally for right side of the pelvis and left for left.

Should you normally feel a hard body in any of the four fornices of the vagina? If so, which one, and what is it?

Yes, in the anterior fornix ; the body of the uterus.

Should you normally feel a hard body in the posterior or either of the lateral fornices?

No.

What mass might you feel in the anterior fornix?

1. A fibroid on anterior wall of the uterus.
2. Inflammatory or blood effusions, rarely.

What mass might you feel in either of the lateral fornices?

Inflammatory deposit from cellulitis or peritonitis.
Blood effusion.
Enlarged tube or ovary.
Body of uterus latero-flexed.
Lateral fibroid.

What mass might you feel in posterior fornix?

Displaced fundus.
Fæces in rectum.
Fibroid on wall of uterus.
Peritonitic or cellulitic deposit.
Hæmatocele.
Displaced ovary.
Tumor.

Rectal Examination.

What are the methods?

1. Simple rectal.
2. Abdomino-rectal.
3. Simon's method.

What are the preliminaries to any rectal examination?

Have bowels empty.
Tell patient what you are to do.

Have soap under finger-nail.
Lubricate finger.

How would you perform the simple rectal examination?

Having observed the preceding preliminaries, pass the finger forward, noting the presence or absence of hemorrhoids, fissures, polypi, stricture, etc., till the cervix is felt, then pass along posterior wall of the uterus.

How would you perform the abdomino-rectal examination?

Passing the right index finger into the rectum as just described, use the left hand externally, placed on the abdomen as in the ordinary bimanual.

What is Simon's method?

This consists in passing the whole hand, shaped like a cone, gradually through the anus into the rectum.

What is the value of the different methods of rectal examination?

Both the simple rectal and abdomino-rectal are of especial value in virgins, where the ordinary bimanual is painful or objected to.

By means of a volsella forceps you may draw down the cervix, and then, with finger in the rectum, palpate the posterior surface of uterus, tubes and ovaries.

The above methods of rectal examination are of value in any case where you wish to reach higher than is possible with the ordinary bimanual.

Advantage is sometimes gained by making the rectal examination with patient in Sims' position.

Simon's method is dangerous and seldom justifiable.

INSTRUMENTS.

Specula.

What are the three classes of specula in most common use?

1. The Spatular.
2. The Cylindrical.
3. The Bivalve.

Give one of the best examples of the spatular variety; describe it.

The Sims speculum (see Fig. 5) is the best example of this class; it consists of two blades united by a handle at right angles to them, the blades being convex on the sides facing each other, concave on the opposite. Many modifications are made by which the length of blade, angle at which it joins the shaft, and weight of the whole instrument are altered. One blade of the Sims speculum is usually made shorter and smaller than the other.

Fig. 5.

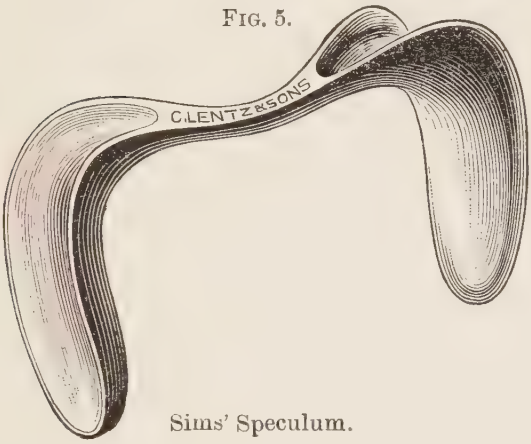

Sims' Speculum.

What are the advantages of Sims' speculum?

It does not distort cervix.

It gives a good view of all but the posterior vaginal wall, and is the best suited for operations on cervix and anterior vaginal wall.

What are the disadvantages of Sims' speculum?

It requires an assistant with some training to hold it.

It requires, in most cases, the use of a vaginal depressor, thus employing one hand.

What is the proper position of the patient for the use of Sims' speculum?

A patient in the so-called "Sims position" should lie on her left side, with left buttock on the left corner of the table, as you face it; the head being at the right corner of the head of the table, the left arm behind the patient; the right arm should lie over the right edge of the table, the right shoulder being kept as near the table as possible. The knees should be drawn up, the right a little above the left.

How would you introduce a Sims speculum?

Having placed the patient in the correct Sims position, select the blade you are to use; warm and lubricate the convex side of it;

FIG. 6.

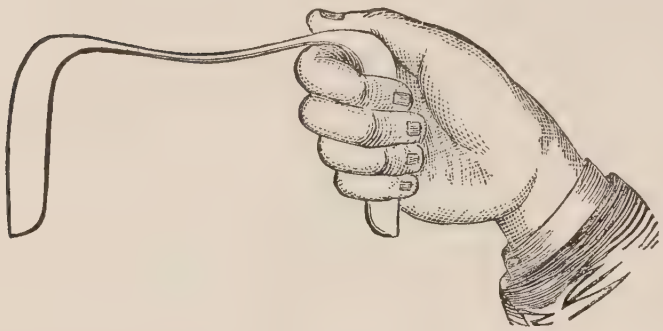

take the speculum in the right hand with the index finger lying in the concavity of the blade, and introduce finger and blade together. The breadth of the blade should be in line with the labia until it has entered the vaginal orifice; it should then be rotated till the convexity lies in apposition with the posterior vaginal wall, which it should hug closely till the posterior fornix is reached and the index finger detects the cervix in front of it; the speculum is then given to an assistant to hold. Some introduce the finger first and pass the blade along it.

FIG. 7.

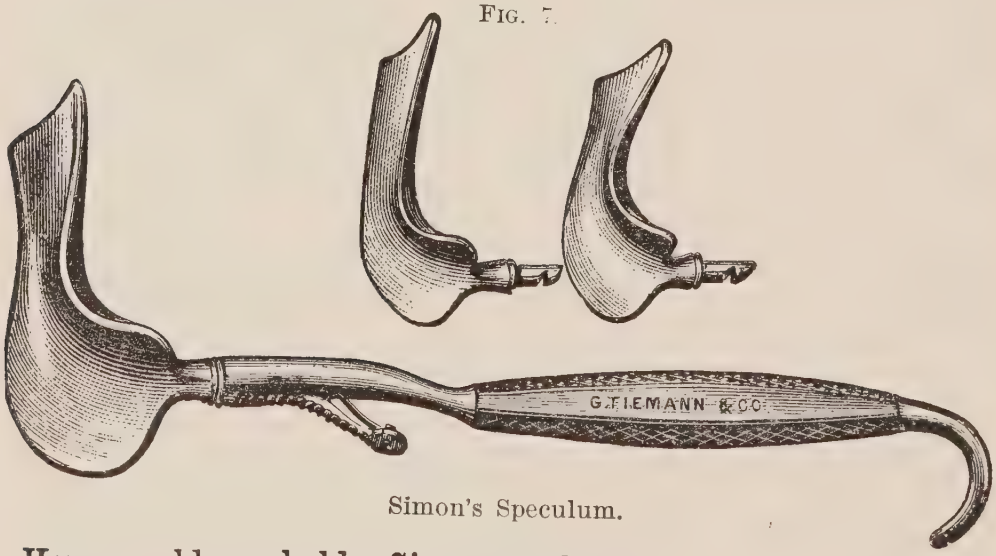

Simon's Speculum.

How would you hold a Sims speculum?

There are two methods in common use:—

(*a*) One is to grasp the outside blade with the right hand, the angle between blade and handle fitting over index finger, as seen in Fig. 6; the thumb lying in the concavity of the blade over the angle.

The right buttock should be raised with the left hand.

(*b*) The other method is to grasp the handle of the speculum with the right hand, having the convexity of the outside blade rest in the hollow between the thumb and index finger.

The right buttock being raised as in the other method.

What is a Simon's speculum?

A very valuable speculum of the spatular variety is called Simon's (see Fig. 7.) It consists of a common handle into which fit, at right angles to it, blades of different sizes and shapes. It is of especial value with the patient in the dorsal position, for retracting the perineum in curetting the uterus or operating upon the cervix.

Fig. 8.

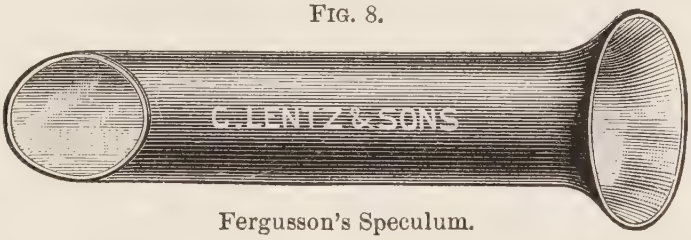

Fergusson's Speculum.

What is one of the best examples of a cylindrical speculum? Describe it.

The cylindrical speculum of Fergusson (see Fig. 8) is probably the best of its class; it is a cylinder of glass or hard rubber, with one extremity beveled and the other trumpet-shaped.

The glass ones usually present a mirrored surface from within.

The beveled extremity is the one first introduced.

What are the merits of the Fergusson speculum?

It is of very limited use; it may be employed for inspecting the cervix or making applications to it. It is useless for operations on the cervix; it is only partially self-retaining, and its introduction in nulliparæ is painful.

How would you introduce a Fergusson speculum?

In this country the Fergusson speculum is usually employed with the patient in the dorsal position.

Separate the labia with the fingers of the left hand; holding the trumpet-shaped extremity with the right hand, introduce the beveled extremity into the vaginal orifice having the shorter side

anterior; depress well the perineum, directing the speculum toward the hollow of the sacrum; by slight vertical, horizontal or rotatory motion of the speculum while looking into it, the cervix is now usually brought into view without difficulty. It is occasionally convenient to draw the cervix more fully into view by means of a tenaculum.

Some gynæcologists use the Fergusson speculum with the patient in Sims' position.

Fig. 9.

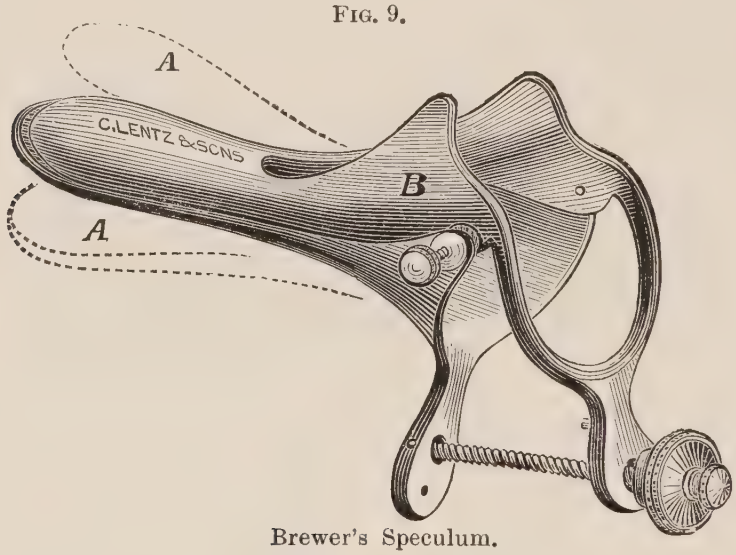

Brewer's Speculum.

What is one of the best examples of a bivalve speculum? Describe it.

The Brewer bivalve (see Fig. 9) is probably the best speculum of its class; it consists of two blades, the outer extremities being trumpet-shaped where they are jointed; the anterior blade is shorter than the posterior, and has a slot in its outer half, to avoid pressure on the urethra; this also facilitates the introduction of the sound or probe. The speculum is opened by approximating the handles of the blades and held there by a thumb-screw. There are two sizes of Brewer's speculum, the long and short.

How would you introduce a Brewer speculum?

Place patient in dorsal position; pass speculum into vaginal orifice with the blades lateral, then rotate till they are antero-posterior; begin to open blades just before they reach the cervix; when completely open, hold with thumb-screw.

What are the merits of Brewer's speculum?

For inspection of, and applications to, the cervix, it is very valuable; it is self-retaining, thus obviating the necessity of an assistant.

The long instrument is better than the short, as with it the vaginal walls are not as likely to obstruct the view by falling in beyond the blades, and at the same time it accomplishes all that the short instrument does.

What are the disadvantages of Brewer's speculum?

It distorts the cervix, obscures the anterior vaginal wall, and cannot be used for operations on the cervix or vagina.

What is the best speculum for examination of the interior of the bladder?

The simplest and best speculum for direct inspection of the interior of the bladder is that devised by Dr. Kelly, of Baltimore

Fig. 9½.

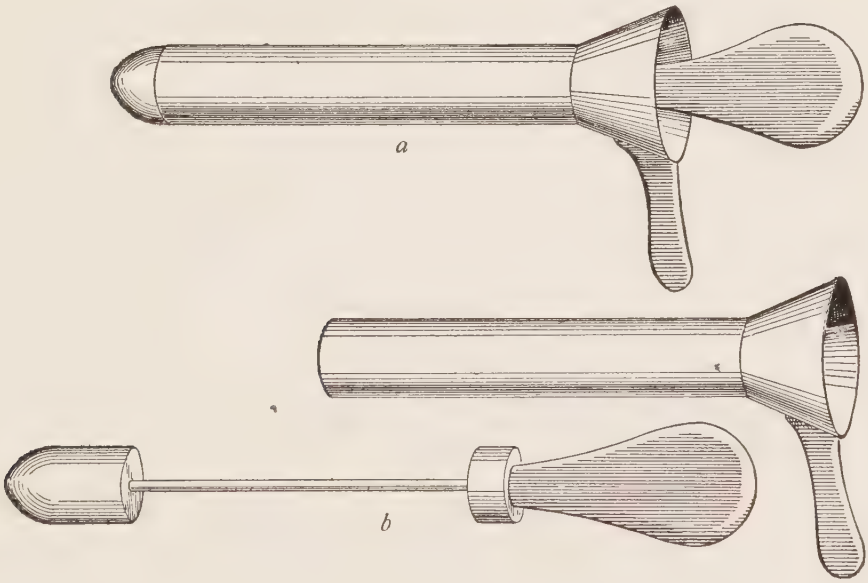

Kelly's speculum ready for introduction (*a*); *b*, speculum with obturator removed.

(Fig. 9½). It is a tubular speculum with obturator, and comes in several sizes.

Describe its use.

The bladder is emptied; the patient is placed in an exaggerated

lithotomy position, with hips elevated 8 to 16 inches above the table. One of the smaller sized specula is introduced, and then a larger, until the desired size is reached. The obturator is then withdrawn, and air enters and distends the bladder. The residual urine is removed by pledgets of cotton held in long thumb-forceps; light is thrown into the bladder by means of a forehead mirror, and by turning the speculum in different directions nearly the whole of the interior of the bladder may be inspected, and through the speculum the ureters may be catheterized.

Fig. 10.

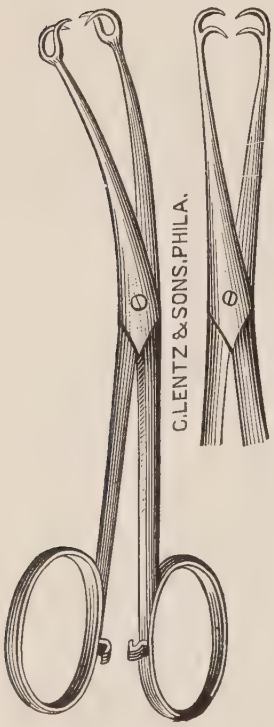

The Volsella.

For a thorough examination anæsthesia is desirable.

Sometimes during such an examination the bladder will not distend sufficiently with air. In such cases the object can be accomplished by putting the patient in the knee-chest position.

Volsella.

Describe it.

The Volsella, or vulsellum forceps (see Fig. 10) consists of a pair of hooks with scissor handles and joint; the hooks usually consist of two or more teeth; the handles fasten with a catch.

What are the uses of the Volsella?

In all operations on the cervix, trachelorrhaphy, dilatation, etc., the volsella, or one of its substitutes, is almost indispensable, to draw down and hold the cervix.

For applications to, or operations on, the interior of the body of the uterus, the volsella is also of great value.

The use of the volsella to draw down the cervix, in connection with the finger in the rectum, in the combined rectal examination, is of great importance.

How would you introduce and apply the Volsella?

If used in operations on the cervix with the patient in the Sims position, it may be introduced either without or with the use of the speculum; if without the speculum, the first two fingers of the right

hand are introduced till the anterior lip of the cervix is felt; the volsella is then passed along them and applied to the anterior lip, which is then drawn down.

The better way is usually to employ Sims' speculum and apply the volsella directly to the anterior lip by sight.

The volsella is also employed with the patient in the dorsal position, the instrument being introduced either by touch, or sight aided by a perineal retractor.

What could you substitute for a Volsella?

A bullet forceps with a catch makes a very good substitute for a volsella and is getting to be preferred to it, as, having but one pair of teeth, it occupies less space on the cervix.

A tenaculum, such as Sims', which is a sharp hook on a long slender shank, is often of great use in holding the cervix and drawing it in any direction, and can sometimes be substituted for a volsella.

Uterine Sound.

What are the two sounds in most general use? their description and merits?

The Sir J. Y. Simpson's sound and that of A. R. Simpson are the two in most general use.

Fig. 11.

Sir J. Y. Simpson's Sound.

They are both rods of copper, nickel-plated, and so pliable that they can easily be bent with the fingers.

The sound of Sir J. Y. Simpson (see Fig. 11) is 12 inches long, with a notched knob 2½ inches from the end, and notches at 3½, 4½, etc., up to 8½ inches,

The handle is roughened on the side of the concavity of the curve.

The sound of A. R. Simpson (see Fig. 12) is only 9 inches long; it has a prominent ring at $2\frac{1}{2}$ inches and two rings at $4\frac{1}{2}$ inches; there are also markings at $3\frac{1}{2}$ and $5\frac{1}{2}$ inches. This sound has an advantage over the preceding in that, being only 9 inches long, the handle, which is broad, can rest firmly on the ball of the little finger even when the tip of the index finger is on the $2\frac{1}{2}$ inch ring, thus giving one a complete control of the instrument when the finger is in the vagina with the sound. This is impossible with the sound of

FIG. 12.



A. R. Simpson's Sound. (*Hart and Barbour.*)

Sir J. Y. Simpson, as in similar circumstances the handle is far above the hand, and one can only grasp the shank, which readily rotates. The presence of the double ring is also an advantage in an enlarged uterus.

What are the contraindications to the use of the sound?

Patient has skipped a menstrual period.
Menstruation present.
Acute inflammation present in uterus or neighborhood.
Malignant disease of uterus.

What are the preliminaries to the use of the sound?

1. Thoroughly sterilize the sound.
2. Be sure that the patient has not skipped a menstrual period.

3. Determine position of uterus by a careful examination.

4. Curve sound to the curve of the uterus.

5. Cleanse the vagina with an antiseptic solution. This is of importance to avoid carrying septic material from vagina to uterus by the sound. For this reason it is always wiser to introduce the sound with the aid of a speculum, which separates the vaginal walls and enables you to reach the os directly.

6. Position of the patient :—

This is largely a matter of choice, but in this country the dorsal position is usually selected, and it has the advantage that in this position the bimanual may be easily combined with the use of the sound.

How would you introduce the sound with patient in the dorsal position?

Having introduced a speculum and thoroughly cleansed the vagina, be sure your sound is aseptic and then pass it by sight directly into the os. The introduction is often most easily accomplished if the uterine body lies forward by starting the sound with its concavity backward, then, when the point is engaged in the cervical canal, turning the sound, not by rotating the shank, but by making the handle describe a semicircle from behind, to the left and forward; the point of the instrument remaining nearly stationary. By depressing the handle toward the perineum, the sound will then usually pass without trouble. If the point catches in the crypts of the cervix, slight motion will usually disengage it.

What variation in this procedure would you make if the fundus lay posteriorly?

Having introduced the sound into the cervix as before, with concavity backward, continue the introduction without the semicircular motion of the handle.

In this position of the fundus the sound is sometimes most easily introduced by a maneuver similar to that in the preceding case but in the opposite direction, viz., starting with the concavity of the sound forward, make the handle describe a semicircle from before backward.

How would you pass the sound in a marked case of anteflexion?

If the uterus is anteflexed, the introduction of the sound is facilitated by curving the sound sharply, and drawing down and steadying the cervix with a bullet forceps.

How would you introduce the sound with patient in Sims' position?

Here, as in the dorsal position of the patient, the introduction of the sound should be preceded by the introduction of the speculum and the cleansing of the vagina and cervix; the sound rendered aseptic is then passed by sight directly into the os without being allowed to touch the vaginal walls; in this way the introduction of sepsis into the uterus is avoided. The further introduction of the sound may be continued with the concavity forward, or starting with the concavity backward the semicircular motion of the handle from behind forward may sometimes be employed with advantage.

If the uterus lies posterior, the sound can usually be introduced directly with its concavity backward.

What are the uses of the uterine sound?

(*a*) To determine—1. The length of uterine canal.
2. Its permeability.
3. Its direction.
4. Condition of endometrium.
5. Growths in uterus.
6. Relation of uterus to tumors.

(*b*) To replace a displaced uterus.

The mobility of the uterus and the relation of cervix and body should be determined by the bimanual, not by the sound.

The sound is wisely much less used now than formerly.

What are the dangers in the use of the sound?

1. Pelvic peritonitis or cellulitis, from introduction of sepsis.
2. Abortion.
3. Hemorrhage, especially in malignant disease.
4. Perforation of uterine walls.

Uterine Probe.

Give its description and uses.

The uterine probe is usually a slimmer instrument than the sound, made of silver, hard rubber or whalebone, with end slightly bulbous. Except in cases of stenosis, it is harder to introduce than the sound, and of less general value. It should be introduced by sight, while cervix is steadied with a tenaculum.

Uterine Applicator.

Give its description and uses.

It is usually made of a piece of flexible steel or copper wire flattened at one end and attached to a handle at the other. It is used to apply medication to the uterine mucosa. The applicator is thrust into a small piece of cotton held between the thumb and finger. It is then rotated until the cotton is so firmly twisted about the end that it cannot be easily pulled off. It is then dipped into the fluid to be used and inserted in the same manner as the uterine sound. As a general rule it is safer to make such applications only to the cervix.

Dilators.

What are the methods of dilating the cervical canal?

1. By tents.
2. By graduated hard dilators.
3. By dilators of the glove-stretcher variety.
4. By elastic dilators—Barnes' bag or Allen's pump.

Tents.

What do you mean by a tent as employed in gynæcology? Give the varieties in use.

A tent is a cone of some expansile material, which, by absorption of moisture, expands after introduction into the cervix sufficiently, both in extent and force, to dilate the canal.

There are several varieties of tents in use, named according to their material.

1. Sponge.
2. Sea-tangle (Laminaria digitata).
3. Tupelo (Nyssa aquatilis).
4. Cornstalk.

What are the merits of each?

The sponge tent expands easily, but it is the most dangerous of all, from the fact that it absorbs so readily material which easily becomes septic.

The sea-tangle tent is less dangerous than the preceding, and dilates well, but it expands unevenly, and its edges are rough after expansion.

The tupelo tent is the best of all. It expands evenly and smoothly, and is the least liable to cause sepsis.

The cornstalk is feeble in action and seldom used.

What are the indications for the use of tents?

1. To dilate the cervical canal for purposes of diagnosis or operation.

2 To check hemorrhage.

What are the merits of tents for these uses?

The employment of tents has greatly, and very wisely, diminished of late. For diagnostic purposes they are still occasionally employed to dilate the cervical canal, so that the finger can be introduced, but they are dangerous, slow and painful, and we have, in most cases, better means, in dilators of the glove-stretcher variety, for accomplishing the same result.

The use of tents to check hemorrhage was chiefly in abortion ; the dilatation of the canal being sought for at the same time. We now have better means.

What are the preliminaries to the use of tents?

All antiseptic precautions should be observed. Patient should have an antiseptic vaginal douche.

You should determine accurately the position of the uterus.

Tents should be curved to the direction of the canal.

A string should be passed through the tent, for ease in withdrawal.

Patient should be in Sims' position.

How would you introduce a tent?

1. Introduce Sims' speculum; draw down cervix with volsella, then taking the tent in a pair of dressing forceps or on a tent carrier, pass it into cervical canal by sight; insert a tampon and give an opium suppository.

What should be the future treatment of the case?

Tents should not be left in over 6–12 hours; sponge tents not over 6 hours. In removing a tent, do not rotate it.

Patient must remain in bed for 24 hours, and not leave the house for 3–4 days.

Graduated Hard Dilators.

Describe them.

There are several varieties in common use, among which are Peaslee's, Kammerer's, Hank's, etc.

The first two resemble male sounds, except that the curve is less acute, and at 2½ inches there is a bulb.

Hank's dilators consist of two sounds on each handle, one at each end. They are often made in sets of six and of hard rubber.

Ordinary male sounds, Nos. 15 to 18, French, may often be substituted for the dilators just mentioned.

What are indications for the use of graduated hard dilators?

1. By themselves to dilate a stenosis of the cervix causing dysmenorrhœa or sterility. Under stenosis here is included that caused by flexions.

2. To maintain a dilatation produced by one of the more powerful dilators.

Describe the mode of employment of these graduated hard dilators.

Place the patient in the dorsal position; thoroughly cleanse the vagina and expose the cervix with a speculum; draw down and hold cervix with a tenaculum or volsella; introduce dilator by sight, as

you would the uterine sound, beginning with the smallest size and increasing to the largest. Pack the vagina loosely with iodoform gauze or sterilized gauze.

In employing these graduated dilators for stenosis of cervix causing obstructive dysmenorrhœa, how often should they be introduced?

It is usually necessary to introduce them once a week during the first month, and once or twice a month for a few months afterward; exercising each time the same antiseptic precautions.

Describe the dilators of the glove-stretcher variety.

The two chief styles of these are the Sims and Ellinger's; in the latter of which the blades are caused to move parallel, and on the handle there is a graduated scale. There are numerous modifications of these dilators, among which may be mentioned Wylie's and Goodell's.

What are the indications for the employment of these dilators?

The same indications obtain as for the preceding, and in addition where a more complete dilatation of the cervix is desired.

The first and more complete dilatation is often performed with a dilator of this class, and then the dilatation maintained by the graduated hard dilators.

What are the preliminaries to the use of the glove-stretcher dilators?

The patient should have an antiseptic douche, and for complete dilatation, anæsthesia.

Describe the method of employing these dilators.

The patient is usually placed in the dorsal position. Retract the perineum with a Simon's speculum; thoroughly cleanse the vagina and cervix; draw down and steady the cervix with a bullet forceps and introduce dilator to the shoulder, separate blades gradually to the desired extent, being careful that the instrument does not slip suddenly and lacerate the cervix. While most of the dilatation is performed in the lateral-diameter of the cervix, it is often well to rotate the dilator and dilate somewhat in other diameters. The

dilatation may also be performed with the patient in Sims' position and with the aid of Sims' speculum.

To what extent should you carry the dilatation?

Usually from ½ to 1 inch.

ELASTIC DILATORS.

Barnes' Bags, Allen's Pump.

Describe them and the method of using them.

They consist of India-rubber bags, of different sizes, the former being fiddle-shaped, the latter more elongated. They are introduced under strict antiseptic precautions, in a collapsed condition, and are then slowly distended with air or water, usually the former; the Barnes' bags by means of a Davidson's syringe, Allen's by the pump.

What are the advantages of these elastic dilators?

Their method more closely resembles the physiological method of dilating the cervix; the dilatation can be made extensive; the danger of laceration of the cervix is slight.

What are the dangers of mechanical dilatation?

Laceration of the cervix.
Endometritis.
Salpingitis.
Peritonitis.

Stem Pessaries.

Describe them and their uses.

They consist of a hard-rubber or non-corrosive metal rod about 1¾ inches long, at one end of which a wide flange projects to keep the pessary from slipping too far into the uterus. There is usually a groove in the rod or else it is hollow to allow the escape of secretion. Their use, which is to maintain a dilatation of the cervix, accomplished in one of the above-mentioned ways, is attended with considerable danger.

The Curette.

Describe it.

The curette consists usually of a loop of wire, either blunt or sharp, on a rather long shank, used for scraping irregularities or new growths from the endometrium.

Occasionally, it is made like a small cup, with a sharp edge, attached to a long shank. Simon's spoon is of this description.

What are the varieties in common use?

Thomas' wire loop, dull and flexible.
Sims' curette.
Recamier curette.
Simon's spoon.

What is the value of the curette?

It is a very valuable instrument, both for diagnosis and treatment.

a. For diagnosis, to scrape away some of the contents of the uterus for examination, to determine the cause of hemorrhage.

b. For treatment, to scrape away villous growths, which, by their vascularity, easily cause hemorrhage.

In malignant disease of the uterus, the curette is also of value to remove sloughing masses.

What are the preliminaries to the use of the curette?

The patient should be anæsthetized, placed in the dorsal position on a Kelly's pad, and knees supported with a leg-holder. The vagina should be scrubbed with soap and water; an antiseptic douche should be given, and all antiseptic precautions should be observed in regard to instruments, hands, etc.

The perineum should be retracted with a Simon's or Sims' speculum; cervix drawn down and steadied with a bullet forceps, then dilated.

A gentle curettage can sometimes be performed without anæsthesia, but for the thorough operation anæsthesia is usually necessary.

Describe briefly the method of curettage.

After dilatation of the cervix, the curette should be introduced very gently until the fundus of the uterus is reached, then withdrawn with the working edge of the instrument pressed firmly against the wall of the uterus. This process is repeated until the walls of the uterus feel smooth. The cavity of the uterus should

then be irrigated with an aseptic or antiseptic solution. If necessary to check hemorrhage or to maintain dilatation a strip of gauze may then be introduced. As a rule, gauze packing in the uterus hinders rather than helps drainage of its cavity. The patient should be confined to bed for several days.

What are the dangers of the curette?

Perforation of the uterus; septic inflammation of the uterus or its adnexa; peritonitis.

Vulvitis.

What are the varieties?

a. Occurring in both children and adults:
1. Simple catarrhal, acute or chronic
2. Gonorrhœal;
3. Phlegmonous;
4. Croupous;
5. Gangrenous;

b. Occurring in adults: Follicular.

I. Acute Simple Catarrhal Vulvitis

What are the causes?

Lack of cleanliness;
Strumous diathesis;
Discharges from cervix, or vagina;
Injuries or friction from exercise;
Masturbation;
Awkward, or excessive coitus;
Pregnancy;
Foreign bodies;
Parasites;
Acute exanthemata.

What are the symptoms?

General malaise; some local pain and burning; parts are œdematous, congested, covered with a glairy, mucous, excoriating discharge, which may extend to the urethra.

What is the treatment?

Rest in bed; warm sitz-baths; lead and opium wash frequently applied to the vulva; lint soaked in it kept between the labia. Bis-

muth, starch, or borax may with advantage be dusted on the vulva in the intervals between the applications of the lead and opium wash. If the vulvitis is from ascarides, employ enemata of infusion of quassia, ℥ij–Oj.

Chronic Catarrhal Vulvitis.

Describe its occurrence and course.

Catarrhal vulvitis in children is most apt to be chronic; it is seen most frequently in strumous children, often with no history of the acute stage.

What are the symptoms?

1. Discomfort in walking and in micturition;
2. Pruritus;
3. Stains on linen.

What is the treatment?

Build up the constitution by tonics and fresh air; observe cleanliness; if much discomfort, use lead and opium wash, followed later by nitrate of silver (gr. x–℥j) applied to the vulva; bismuth or borax being dusted on between the lotions.

II. Gonorrhœal Vulvitis.

What is the etiology?

It is produced either directly by intercourse with one who has contracted gonorrhœa, or indirectly by soiled linen, instruments, etc.

What is the diagnostic value of Neisser's gonococcus, found in the discharge?

The gonococcus of Neisser is the sole cause of gonorrhœa, and the disease can only be transmitted through its agency.

Give an account of the gonococcus and its inflammations.

The gonococcus is a diplococcus pathogenic only for man. It is found in the discharges of gonorrhœal inflammations and is usually contained in the cell body of pus cells.

It is not stained by Gram's method, and grows only on culture-media containing blood-serum.

Its usual inflammations are those of the genital tract, but it may cause conjunctivitis, synovitis, or malignant endocarditis. The gonococcus very rarely produces a general peritonitis.

It is doubtful whether it is ever the direct cause of cystitis.

It is rarely found associated with other bacteria in its lesions. The female genital organs most often the seat of gonorrhœa are the urethra, vulvo-vaginal glands, cervical and corporeal endometrium, and the Fallopian tubes.

Upon what points would you base a diagnosis of gonorrhœa in the female?

Absence of history of labor, abortion or use of instruments, sudden onset of symptoms, moderate rise of temperature, as a rule, without chill, yellow purulent discharge, urethritis, Bartholinitis, or redness about the orifice of its duct. Any or all of these signs may be present. The diagnosis becomes positive when the gonococcus can be identified. It is best sought for in the urethral pus.

What is the differential diagnosis between gonorrhœal vulvitis and acute simple catarrhal vulvitis?

In gonorrhœal vulvitis, the onset is more violent; more fever, pain, and œdema; the inflammation extends up the vagina, urethra, and vulvo-vaginal glands; pus can often be pressed out of the urethra; gonococci can be found in the discharge; often warts or buboes are present, and sometimes gonorrhœal rheumatism.

What is the treatment of gonorrhœal vulvitis?

Keep patient quiet; give light diet; keep bowels open; disinfect the parts with bichloride 1–5000, or lysol 1–100 or 200; then have the parts irrigated every hour or two with borax water ʒj–Oj. If discomfort is very great, lead and opium wash may be frequently applied to the vulva, and patient may take warm sitz-baths. The labia should be kept separated with lint or gauze smeared with some simple antiseptic ointment.

If the vulvitis tends to become chronic, apply nitrate of silver, gr. x–xx–℥j.

III. Phlegmonous Vulvitis.

What is the etiology?

It may arise from the following:—

Traumatism;
Irritating discharges;
Acute exanthemata;
Furunculosis.

What are its pathology and symptoms?

It is a circumscribed or diffuse suppurative process manifesting itself by the following symptoms:—

a. Subjective: Heat and pain, increased by standing or walking.

b. Objective: Congestion, swelling, induration; later, suppuration.

From what must you differentiate phlegmonous vulvitis?

a. Pudendal hernia;
b. Dislocated ovary;
c. Hydrocele of round ligament;
d. Hæmatoma of vulva.

How would you differentiate phlegmonous vulvitis from pudendal hernia?

Phlegmonous Vulvitis vs.	*Pudendal Hernia.*
Signs of acute inflammation.	None unless strangulated, or injured.
Dullness on percussion.	Tympanitic on percussion.
No impulse on coughing.	Impulse on coughing.
Not reducible.	Usually reducible.
History of traumatism, etc.	History of strain.

How would you differentiate phlegmonous vulvitis from a dislocated ovary?

Phlegmonous Vulvitis vs.	*Dislocated Ovary.*
Signs of acute inflammation.	Usually absent.
Gradual development.	Sudden development.
No especial exacerbation during menstruation.	Larger and more sensitive during menstruation.
No sense of ovarian compression when pressed upon.	Peculiar sensation when pressed.
Not the shape of an ovary.	Has the shape of an ovary.

How would you differentiate phlegmonous vulvitis from hydrocele of the round ligament?

Phlegmonous Vulvitis	*vs. Hydrocele of Round Ligament.*
Signs of acute inflammation.	No signs of acute inflammation.
Opaque.	Translucent.
Never communicates with abdominal cavity.	Sometimes communicates with abdominal cavity.

How would you differentiate phlegmonous vulvitis from hæmatoma of vulva?

Phlegmonous Vulvitis	*vs. Hœmatoma of Vulva.*
Gradual formation.	Sudden onset.
Less frequent during parturition.	More frequent during parturition.
Color, red.	Color, purplish.
First hard, then soft.	First soft, then hard.
Less often preceded by varicosities.	More often preceded by varicosities.

What is the treatment of phlegmonous vulvitis?

Tonics: Arsenic, quinine, etc.

Wet antiseptic dressings, as gauze soaked in cool aluminium acetate solution. When pus has formed, open, drain, and dress antiseptically.

IV. Croupous Vulvitis.

Give the etiology, symptoms, and treatment.

A vulvar inflammation with the formation of a false membrane may be due to diphtheria or other infectious disease, including puerperal infection. True diphtheria may appear first on the vulva, the membrane resembling that of pharyngeal diphtheria. The treatment is that of the infectious disease with local use of antiseptics.

V. Gangrenous Vulvitis.

Give the etiology and treatment.

Gangrenous vulvitis is most frequently found complicating pregnancy, severe types of acute exanthemata, and very violent cases of vulvitis of other varieties. The treatment consists of constitutional tonics and local antiseptics.

VI. Follicular Vulvitis.

Give the pathology.

Follicular vulvitis is an inflammation of the mucous and sebaceous glands and hair follicles of the vulva; all may be simultaneously affected, or one set alone involved.

What is the etiology?

It occurs only in adults; any of the causes of simple acute catarrhal vulvitis may produce it; among the most common are the following:—

a. Lack of cleanliness;
b. Discharges from above, especially senile leucorrhœa;
c. Pregnancy;
d. Acute exanthemata.

What are the symptoms?

a. Subjective:—
Local heat and pain;
Pruritus;
Increased secretion;
Hyperæsthesia;
Vaginismus occasionally present;
Vulvar extremity of urethra is sometimes affected, then ardor urinæ results.

b. Objective:—

The mucous membrane appears very red in spots, resembling the papillæ of the tongue. When the sebaceous glands and hair follicles are chiefly affected, they will be found as little round red papillæ, scattered over labia and base of prepuce and clitoris, not on vestibule; later, a drop of pus appears in the apex of these papillæ; they then disappear.

How would you treat a case of follicular vulvitis?

Pay strict attention to cleanliness; during the acute stage use mild antiseptic lotions, as borax water (ʒj–Oj) or alum-acetate solution; later, apply nitrate of silver (gr. x–℥j). Bismuth or calomel may be used as a dusting powder; keep labia separated.

Cyst and Abscess of Vulvo-vaginal Gland.

Cyst of Vulvo-vaginal Gland.

Give the etiology and pathology.

A cyst of the Bartholinian or vulvo-vaginal gland is formed by a distention of the duct, or gland itself, caused by any occlusion of the duct, especially from inflammation, either simple catarrhal or gonorrhœal. A cyst of the duct is more elongated than of the gland itself; a cyst of the gland is occasionally multiple.

Abscess of the Vulvo-vaginal Gland.

What is the etiology?

The causes of a vulvitis may produce abscess of the vulvo-vaginal gland; gonorrhœa is the most common cause.

What are the symptoms?

Pain; heat; swelling and redness, especially near orifice of duct; it is tender on pressure; at first hard, later fluctuating.

How could you differentiate a cyst from an abscess of the vulvo-vaginal gland?

Cyst	*vs.* *Abscess.*
Gives no signs of inflammation.	Shows inflammation.
Insensitive to pressure.	Sensitive to pressure.
Duration long.	Duration shorter.

What is the treatment of a cyst of the vulvo-vaginal gland?

The usual treatment is to excise an elliptical area of mucous membrane over the sac on its inner surface; this exposes the sac; now cut out a large ellipse from it; empty the sac, pack it with iodoform gauze, and apply an antiseptic outside dressing.

A better plan is usually to dissect out the whole sac, if possible, and bring together the edges of the wound with catgut; then apply an antiseptic dressing as before.

From what may you get considerable hemorrhage in extirpating the sac?

From the transversus perinei artery, and from the bulbs of the vagina.

How would you treat an abscess of the vulvo-vaginal gland?

Before the presence of pus is detected, keep the patient quiet in bed; apply soothing lotions like alum-acetate solution. As soon as pus is detected, proceed as with the cyst till sac is opened, then with a sharp curette scrape the interior of sac wall; irrigate with bichloride (1–1000); pack with iodoform gauze, and apply an antiseptic outside dressing of iodoform gauze, bichloride gauze, absorbent cotton and a T-bandage.

From what must you differentiate vulvo-vaginal cyst or abscess?

From hernia and phlegmonous vulvitis.

How would you differentiate vulvo-vaginal cyst or abscess from hernia?

Cyst or Abscess	*vs.*	*Hernia.*
No impulse on coughing.		Impulse on coughing.
Irreducible.		Usually reducible.
Dull on percussion.		Tympanitic on percussion.
Abscess shows signs of inflammation.		None, unless strangulated, or injured.
More circumscribed.		Less circumscribed.

How would you differentiate abscess of vulvo-vaginal gland from phlegmonous vulvitis?

The vulvo-vaginal abscess is more distinctly circumscribed and globular; the phlegmonous vulvitis is more diffuse.

Pudendal Hernia.

Describe.

The process of peritoneum which follows the round ligament through the inguinal canal to its termination in the labium majus is usually obliterated at birth; occasionally this obliteration does not occur, and this channel, called the canal of Nuck, furnishes a path for hernia. The hernia may consist of intestine, omentum, ovary or bladder. The uterus has even been said to follow this canal.

What are the causes?

Blows, falls, coughing or violent muscular exertion.

What are the symptoms?

The patient experiences a feeling of discomfort, especially on walking, and finds a swelling, which, if intestine, presents the following features: It gives an impulse on coughing; is tympanitic on percussion; can usually be reduced, and, unless strangulated, or injured, presents no signs of inflammation.

If the hernia consists of an ovary, it gives the ovarian sensation on pressure, and its size and tenderness are both increased during menstruation.

What is the treatment?

Place patient on her back, with knees elevated; reduce by gentle taxis, if possible, and apply a suitable truss. If strangulation has occurred, a surgical operation is necessary. If the hernia consists of an ovary which has become adherent, protect it from pressure by a hollow pad, or if it occasions great distress, remove it.

Pudendal Hæmatocele.

What are the synonyms?

Hæmatoma or thrombus of vulva.

Define.

Pudendal hæmatocele (better hæmatoma) consist of an effusion of blood into the tissue of the vulvo-vaginal region, usually into one labium, or into the areolar tissue surrounding the vaginal walls.

What is the etiology?

Pudendal hæmatocele is predisposed to by any condition causing, or accompanied by, a dilatation of the vessels of the vulva:—

Pregnancy;
Tumors;
Varicocele;
Labor.

The exciting causes are blows, falls, muscular efforts, etc.

Describe the symptoms and course.

The patient experiences pain of a tearing character, which, if the

effusion is large, may be accompanied by faintness. Sometimes the effusion presses on the urethra and causes difficulty in micturition. The swelling is at first soft; later, hard.

If small, it is usually absorbed; it sometimes remains for a long time; sometimes suppurates.

How would you differentiate pudendal hæmatocele from hernia?

Pudendal Hæmatocele	*vs.*	*Hernia.*
History.		History.
No impulse on coughing.		Impulse on coughing.
Dull on percussion.		Tympanitic.
Irreducible.		Usually reducible.
First soft, then hard.		More uniform.

How would you treat a case of pudendal hæmatocele?

While effusion is in progress, apply ice and pressure. If the effusion is large, occurs during labor and obstructs the passage of the head, incise, turn out the clots and pack with iodoform gauze. If the effusion is small, apply soothing lotions like alum-acetate solution; if suppuration occurs or if absorption is long delayed, incise, irrigate with an antiseptic solution, and pack with iodoform gauze.

Hemorrhage from Vulva.

What is the etiology?

The predisposing causes are the same as for pudendal hæmatocele and hæmatocele itself. The existing causes are the following:—

Violent muscular efforts;
Blows;
Punctures or lacerations.

What is the treatment?

If it is a ruptured hæmatocele, incise, turn out the clots and pack; otherwise, catch bleeding points and ligature, or apply pressure, assisted by a tampon in the vagina.

Skin Diseases Affecting the Vulva.

What are the most common?

Erythema, eczema, and herpes are most frequently seen; eczema may be acute or chronic.

Erythema of the Vulva.

Give the etiology, symptoms and treatment.

Etiology.—Erythema is most apt to occur in fleshy people, especially in hot weather. The exciting causes are:—

Lack of cleanliness;
Irritating discharges;
Exercise.

Symptoms.—The parts become red, sensitive, often excoriated and painful, especially in walking.

Treatment.—Cleanliness;
Attention to bladder and urine;
Desiccating powders, such as bismuth subnitrate, oxide of zinc, or calomel.

Eczema of the Vulva.

Give the etiology.

Eczema is predisposed to by functional disturbance of the gastro-intestinal tract, gout or rheumatism; it is especially apt to occur in women near the menopause. The most frequent exciting cause is an irritating discharge from the cervix or vagina.

What are the symptoms?

The disease may be acute or chronic. In the acute form, the parts become reddened and œdematous; vesicles appear, break and discharge a thick, tenacious fluid, which forms crusts. The subjective symptoms are severe burning and itching.

In the chronic form, the parts become thickened and scaly; the subjective symptoms resemble those of the acute, but are a little less marked.

What is the treatment?

In the acute form, observe strict cleanliness; if the burning is very severe, use alkaline sitz-baths and sedative lotions; later, or at first if burning and itching are not intense, an ointment like the following is very good:—

℞. Acidi salicylici, ... gr. xv,
Zinci oxidi, ... ʒ ij ss,
Pulv. amyli, ... ʒ ij ss,
Petrolati, ... ℥ j.
M. Sig.—Apply locally.

In the chronic form, use the same treatment during the exacerbations as for the acute; later, an ointment containing oil of cade will be found of value.

What are the most common parasites found on the vulva?

The pediculus pubis, or crab louse, is the parasite most often found infecting the vulva.

The acarus scabiei, or itch mite, is occasionally, but rarely, found on the vulva as part of a general infection.

Give the etiology, symptoms and treatment of infection with pediculi pubis.

Etiology.—The pediculus pubis is almost always conveyed directly from person to person, usually in sexual intercourse.

Symptoms.—There is burning and itching; often an eruption resembling eczema. The diagnosis is made by finding the pediculus closely adherent to the roots of the hair.

Treatment.—Any one of the following:—

Corrosive sublimate, 1–1000;
Tincture of delphinium;
Carbolic 5 per cent. solution.

It is often best to shave the pubes before applying the lotion or ointment.

Give the etiology, symptoms and treatment of scabies of the vulva.

Etiology.—The acarus scabiei is rarely found on the vulva, but this occasionally occurs as part of a general infection.

Symptoms.—There is an intense pruritus, worse when the body is warm. The diagnosis is made by finding the burrows on other parts of the body, especially between the fingers.

Treatment.—A warm soap and water bath, followed by an ointment composed of sulphur alone, or combined with balsam of Peru.

New Growths of the Vulva.

Mention the principal new growths occurring on the vulva?

a. Papillomata—
  1. Simple;
  2. Pointed condylomata;
  3. Syphilitic condylomata.

b. Cyst of vulvo-vaginal gland.
c. Carcinoma.
d. Sarcoma.
e. Elephantiasis.
f. Fibromata.
g. Lipomata.
h. Neuromata.
i. Lupus.

Simple Papillomata.

What is the etiology and treatment?

Etiology.—A simple papilloma, or wart, occurs rarely on the vulva; it is usually congenital and of little importance.

Treatment.—It may be destroyed with nitric acid, or it may be excised under cocaine, and the wound closed with fine sutures.

Pointed Condylomata.

What is the etiology and appearance?

Pointed condylomata, or gonorrhœal warts, are caused by the gonorrhœal poison; they are always multiple, and occur most frequently on the inner surfaces of the labia majora, on the perineum and about the anus; they are of a grayish color and often pediculated;

their summit is divided into pointed lobules. When on the skin, they are sometimes dry and hard; on a mucous surface they are soft. In some cases pointed condylomata appear to arise from an irritating discharge, the gonorrhœal character of which cannot be proved.

What is the treatment of pointed condylomata?

The best treatment is to cut them off with scissors or knife and touch the base with nitric acid; under the use of cocaine this may be made practically painless.

Syphilitic Condylomata.

What is the etiology, appearance and treatment?

Syphilitic condylomata, or mucous patches, are the result of the syphilitic poison. They are broad and flat, situated most frequently on the inner surface of the labia majora, and usually covered with a grayish, mucus-like secretion. According to Duhring, they sometimes take on a more warty growth.

Treatment.—Cleanliness;
Calomel locally;
Constitutional treatment for syphilis.

Pruritus Vulvæ.

Define.

Pruritus vulvæ, a symptom rather than a disease *per se*, consists of an irritation of the nerves of the vulva, accompanied by intense itching, at first localized, later extending, from the mechanical irritation of scratching.

What is the etiology?

The predisposing causes are:—

a. Poor health.

b. Disorders of the digestive tract.

c. Anything producing congestion of the vulva, such as—
Pregnancy;
Tumors in neighborhood;
Diseases of uterus or appendages;
Menopause.

d. Lack of cleanliness.

The exciting causes are chiefly the following :—

1. Irritating discharges from cervix, vagina, urethra or vulva.
2. Diabetic urine.
3. Eruptions.
4. Parasites.
5. Masturbation.
6. Vegetations on vulva.
7. Kraurosis vulvæ. This is an atrophic condition of the vulva whose cause is unknown. It begins about the clitoris, and chiefly involves clitoris, vestibule, and labia minora. There is an increase of fibrous tissue in the mucous membrane, with a disappearance of its papillæ, giving the parts a smooth white appearance. It causes an intense itching and hyperæsthesia.

What are the symptoms ?

An intense itching, at first only at intervals after active exercise, over-indulgence at the table, lying in a warm bed, or sexual intercourse. Later, the itching becomes constant ; the desire to scratch becomes irresistible, causing the patient to avoid society ; it sometimes leads to nervous depression and melancholia.

What is the treatment ?

First ascertain the cause, if possible.

Build up the general health.

Regulate the diet.

Observe strict cleanliness.

Destroy parasites if present.

If sugar present in the urine, give salicylate of soda.

Treat eruptions.

If there is an acid discharge from above, tampon vagina.

Let patient use frequent warm sitz-baths.

Apply any one of the following :—

Hot lead and opium wash ;
Carbolic solution, 2–3 per cent. ;
Bismuth or calomel dusted on vulva ;
Nitrate of silver (gr. x–ʒj) ;
Cocaine, 4 per cent. solution.

Hyperæsthesia of the Vulva.

Describe.

This consists of an excessive sensibility of the nerves supplying the mucous membrane of some portion of the vulva.

What is the etiology?

The menopause seems to predispose to it; also the hysterical and melancholic state. An irritable urethral caruncle sometimes acts as an exciting cause. A peculiar atrophic condition of the skin of nymphæ and vestibule, called krauroses vulvæ, is an occasional cause. Often no cause can be assigned.

What are the symptoms?

Hyperæsthesia, especially about the vestibule and labia minora; there is no pruritus, and signs of inflammation are absent except occasional erythematous spots; dyspareunia is very marked; the slightest friction causes pain.

What is the treatment?

Build up the constitution with tonics, change of air, etc.
Interdict sexual intercourse.
Administer the bromides internally.
Externally apply one of the following:—

Carbolic lotion, 2–3 per cent;
Nitrate of silver solution (gr. x–xx–ʒj);
Lead and opium wash;
Four per cent. solution of cocaine.

Vaginismus.

Define.

Sims defined vaginismus as "an excessive hyperæsthesia of the hymen and vulvar outlet, associated with such involuntary spasmodic contraction of the sphincter vaginæ muscle as to prevent coitus."

What is the pathology?

There are usually found sensitive papillæ about the base of the hymen; an hypertrophy of the papillæ and connective tissue of the hymen; occasionally the lesion seems to be at a distance, as in the uterus or appendages; sometimes no lesion is visible.

What is the etiology?

The predisposing causes are—

1. A narrow vagina.
2. A dense, thick hymen.
3. Malposition of the vulva.

The exciting causes are—

1. Disturbances of the sexual function.
2. Masturbation.
3. Inability of the male to complete the sexual act.

What is the treatment?

Palliative.—Forcibly dilate the hymen, under anæsthesia, by inserting and separating the thumbs; then insert one of Sims' glass vaginal plugs.

Radical.—Excise the hymen and insert one of Sims' plugs.

Coccygodynia.

Define and give the etiology.

Coccygodynia, or coccyodynia, is a "painful affection of the muscles, tendons, and nerves of the coccyx, with or without disease of the bone itself." (Mann).

It occurs most frequently after childbirth, but is also produced by mechanical causes, such as blows, falls, kicks, etc. Among other causes are disease of the pelvic organs, rheumatism and gout. Hysteria largely predisposes to it; in some cases no cause can be assigned.

What are the symptoms?

Pain in the coccygeal region, increased by motion bringing into play the muscles attached to the coccyx; especially rising after sitting, defecation, coitus, sometimes even walking.

Pressure on the coccyx elicits the characteristic pain.

The condition must be differentiated from disease of the rectum or anus, and from pure hysteria.

What is the treatment?

First attend to the general condition, rheumatism, hysteria, etc., if this fails, we have two operations:—

1. Cutting the attachments of the muscles to the coccyx.
2. Extirpation of the coccyx.

Irritable Urethral Caruncle.

Define.

An irritable urethral caruncle is a deep red mass, very vascular and sensitive, situated at the mouth of the urethra, or just within the canal; it consists, according to Hart and Barbour, of dilated capillaries in connective tissue, the whole being covered with squamous epithelium.

What is the etiology?

But little is known of its etiology; it occurs at all ages, and in both married and single women.

What are the symptoms?

The patient complains of frequent and painful micturition; later, this dysuria increases, and pain is caused by walking, pressure or friction of any kind. Intercourse causes both pain and hemorrhage. The nervous symptoms are well-marked; hysteria, melancholia, etc.

On examination, one finds a raspberry-looking mass at the meatus; it is very sensitive and bleeds easily; it may be single or multiple.

From what must you differentiate an irritable urethral caruncle, and how?

From polypi, venereal warts and prolapse of the urethral mucous membrane.

Polypi are usually higher in the urethra, are less vascular and less sensitive.

Venereal warts are less vascular, insensitive, and usually accompanied by others. The history may aid.

Prolapse of the urethral mucous membrane may resemble a caruncle in appearance, but it usually surrounds the meatus more, is less vascular and less sensitive, is continuous with the urethral mucous membrane, and can usually be reduced.

What is the treatment?

Employ anæsthesia; cut off the caruncle and touch the base with nitric acid or the actual cautery. You may ligate before cutting.

What is the prognosis?

If the growth is single and near the meatus, the prognosis is good; if multiple and extending up the urethra, they may recur.

Prolapse of the Urethral Mucous Membrane.

Describe.

Prolapse of the urethral mucous membrane may involve the whole circumference of the meatus, or only a portion; if the latter, it is the lower portion which is usually affected; a slight redundancy at the meatus is common; a prolapse sufficient to form a tumor is rare. At first the exposed mucous membrane is of its normal pink color; later it assumes an angry red color, often becomes excoriated and sensitive; urethritis and cystitis may accompany it.

What is the etiology?

Frequent child-bearing, dilatation of the urethra and a lax condition of the tissue, from whatever cause, undoubtedly predispose to prolapse of the urethral mucous membrane. The exciting causes are usually vesical and rectal irritation, accompanied by straining.

What are the symptoms?

Frequent micturition, which soon becomes painful, tenesmus, and if vesical tenesmus previously existed, it becomes much aggravated.

What is the treatment?

If the prolapse is recent, an attempt at cure may be made by reducing the mucous membrane, keeping the patient quiet in bed, making astringent applications to the urethra and removing the cause of previous vesical or rectal tenesmus, if present.

If these procedures fail, remove the prolapsed portion by one of the following methods:—1. If small, ligate and excise; if more extensive, excise the redundancy and stitch mucous membrane of urethra to the border of the meatus. 2. Emmet's "button-hole" operation. The first method is usually the preferable one.

Malformations of the Vulva.

What are the principal malformations of the vulva?

1. Absence of the vulva.

2. Hypospadias, in which the posterior wall of the urethra is defective.

3. Epispadias, in which the anterior urethral wall is defective, usually combined with a defect in the anterior wall of the bladder.

4. The clitoris may be absent, rudimentary, or hypertrophied.

5. The labia minora may be absent, rudimentary, or greatly hypertrophied, as in the "Hottentot apron."

6. Less often the labia majora may be hypertrophied.

7. No well attested case of true hermaphrodism, *i. e.*, an individual with both ovary and testicle, has ever been reported.

8. Pseudo-hermaphrodism, where the external genitals alone resemble those of both sexes, is more common. These individuals are usually mal-developed males.

Diseases of the Vagina.

Discuss the relation of the normal vagina to bacteria.

The vagina normally contains a number of bacterial species which affect an entrance into it soon after birth. None of these bacteria are pathogenic. If pathogenic ones other than the gonococcus are introduced into the vagina they disappear in a few days, or if they remain longer their virulence is diminished. A number of factors contribute to this result, the chief being the acid reaction and anaerobic condition of the vagina and the bactericidal power of the serum of its secretion.

What are the varieties of inflammation of the vagina?

1. Simple catarrhal vaginitis, or colpitis.
2. Gonorrhœal.
3. Ulcerative, senile or adhesive.
4. Croupous.

Simple Catarrhal Vaginitis.

What is the etiology?

The predisposing causes are—

a. General bad health.

b. Anything causing local congestion, as—

Disease of heart or lungs;
Disease of the pelvic organs;
Pregnancy.

The exciting causes are :—

a. Irritating discharges from the cervix.

b. The use of too hot, too cold or irritating douches.

c. Awkward or excessive coitus.

d. Foreign bodies, as pessaries, tampons, etc.

What are the symptoms?

Simple catarrhal vaginitis may be acute or chronic.

The subjective symptoms of the acute are a feeling of heat in the vagina, pain in the pelvis, and sometimes vesical and rectal irritability.

The objective symptoms are a muco-purulent vaginal discharge which may irritate the vulva; the vagina appears red, perhaps granular or cystic in places.

The chronic form resembles the acute except in degree; in it the subjective symptoms, save itching caused by the leucorrhœa, are usually absent.

What is the treatment of simple catarrhal vaginitis?

In the early stages, keep the patient quiet; keep the bowels open, and give light diet; keep the urine bland by alkaline diluents. If the itching is severe, let the patient take frequent warm alkaline sitz-baths; in addition, irrigation of the vagina with warm water containing either of the following will be found of value: Liquor plumbi subacet. ʒj–Oj; borax ʒj–Oj.

After irrigation it is well to dust some desiccating powder, like bismuth, upon the vulva.

When the vaginitis becomes subacute or chronic, make application to the vagina of nitrate of silver gr. x–xxx–ʒj, or pyroligneous acid.

Let the patient use daily vaginal douches of hot water containing borax, ʒj–Oj; or sulphate of zinc, ʒss–ʒj–Oj; or alum, ʒj–Oj.

The douches should be taken while the patient is in the dorsal position, not sitting.

Gonorrhœal Vaginitis.

How does gonorrhœal vaginitis differ from the simple catarrhal?

a. The onset is usually more acute.

b. The discharge is more purulent, viscid and offensive than in the simple catarrhal.

c. Urethritis is more common.

d. Sometimes a history of exposure to infection can be obtained.

e. Often gonorrhœal warts or buboes are present.

f. The most certain diagnostic point is the presence of gonococci.

What are the frequent complications and results of gonorrhœal vaginitis?

Vulvitis, urethritis, endometritis, salpingitis, ovaritis and peritonitis.

The dangers of gonorrhœal vaginitis have been greatly underestimated.

What is the treatment of gonorrhœal vaginitis?

Keep the patient quiet; attend to diet; move the bowels with salines; keep urine bland. During the acute stage, let the patient have bichloride vaginal douches, 1–10,000, three or four times a day. After the acute stage has passed, thoroughly disinfect the vagina with bichloride, 1–1000, and loosely pack the vagina with sterile gauze to keep the walls separated and the labia apart, thus insuring drainage. Repeat this process every 24 hours until the disease has subsided.

If the condition tends to become chronic, apply nitrate of silver, gr. xx–xxx–ʒj, two or three times a week, letting the patient use daily douches of borax water.

The complicating vulvitis requires its own treatment.

Ulcerative Vaginitis.

Describe.

Ulcerative, senile or adhesive vaginitis is present to a greater or less extent in nearly every woman over 60. It may occur earlier in life.

There is a desquamation of the squamous epithelium in spots, and where these raw areas lie in apposition, adhesion is apt to occur. There is usually a thin leucorrhœa, which irritates the vulva and causes pruritis.

What is the treatment?

The treatment consists in the application to the vagina of such solutions as nitrate of silver, gr. x–xx–ʒj, or pyroligneous acid, and the use by the patient of astringent vaginal douches, such as sulphate of zinc ʒss–Oj, alum ʒj–Oj, or borax ʒj–Oj.

Croupous Vaginitis.

What is the etiology and treatment?

It occurs in conjunction with puerperal infection, diphtheria, and severe forms of the infectious diseases. The treatment is the general treatment of the disease and the local use of antiseptics.

Pelvic Peritoneum.

Describe.

The pelvic peritoneum is a continuation of that lining the inner surface of the walls of the abdomen; it covers, more or less completely, the pelvic organs (the ovary is regarded as not covered by peritoneum), lines the pelvic walls and also the floor of the pelvis. Traced from before backward, in the median line, it leaves the anterior abdominal wall about 1½ inches above the symphysis, is reflected over the fundus of the bladder and down its posterior surface to about the level of the internal os; it then passes over to the uterus, covers its anterior surface above that point, passes over the fundus and down its posterior surface to the vaginal junction, thence down the vaginal wall for about an inch; it then passes to the rectum, covers the anterior surface of the middle portion, and surrounds the upper portion completely. The pelvic peritoneum is thrown into several folds and forms several pouches.

Describe the folds and pouches of the pelvic peritoneum.

The principal folds are the broad, utero-vesical and utero-sacral

ligaments (so-called). The broad ligaments, extending from the sides of the uterus to the sides of the pelvis, in front of the sacro iliac synchondrosis, divide it into two fossæ, the anterior and posterior; these are also subdivided, the anterior by the utero-vesical ligaments, the posterior by the utero-sacral. The pouch between the utero-vesical ligaments is called the utero-vesical pouch; that between the utero-sacral, the pouch of Douglas, which is the deepest part of the peritoneal cavity.

The pouches between the utero-vesical and broad ligaments are called the para-vesical pouches; those between the utero-sacral and broad ligaments are called by Polk the "retro-ovarian shelves."

Two other pouches are mentioned, which depend on the condition of the bladder: the vesico-abdominal, when the bladder is distended; and the utero-abdominal, when the bladder is empty and contracted.

What are the boundaries of the utero-vesical pouch?

It is bounded in front by the posterior surface of the bladder, behind by the anterior surface of the uterus, and laterally by the utero-vesical ligaments.

What are the boundaries of the pouch of Douglas?

It is bounded in front by the posterior surface of the uterus and the upper portion of the posterior vaginal wall, behind by the rectum, and laterally by the utero-sacral ligaments.

What are the boundaries of the retro-ovarian shelves?

They are triangular in shape, bounded in front by the base of the broad ligament, internally by the utero-sacral ligament, and externally by the wall of the pelvis.

Pelvic Peritonitis.

What is the pathology?

The peritoneum first becomes hyperæmic; it loses its lustre, and exudation materials are poured out.

1. There may be scarcely any serum exuded; the inflamed area is coated with fibrin, and adhesions form, binding together the pelvic organs and intestines.

2. The exudation may consist largely of serum, either free in the peritoneal cavity, or encapsulated by adhesions.

3. The exudation in severe, especially septic cases is often purulent.

Hence the varieties :—

a. Adhesive.
b. Serous.
d. Purulent.

What is the etiology?

In a general way, the etiology of pelvic peritonitis may be stated as an extension to the peritoneum of inflammation of the uterus, ovaries or tubes ; in a large majority of the cases, inflammation of the tubes.

There is, usually, first an endometritis, then a salpingitis, and then a peritonitis.

Individual causes are as follows :—

a. Introduction of sepsis during parturition, abortion or operations.

b. Gonorrhœa.

c. Introduction into the uterus of septic instruments.

d. Injection of fluids through uterus and tubes into the peritoneal cavity.

e. Catching cold during menstruation.

f. Tubercular or cancerous disease of the pelvic organs.

g. Tumors causing irritation of the peritoneum.

h. Pelvic cellulitis and peritonitis are often associated as being produced by the same causes.

What are the symptoms?

Pelvic peritonitis may be either acute or chronic.

Acute pelvic peritonitis is usually ushered in by a rigor; this, however, is not always present. There are pain and tenderness in the lower part of the abdomen ; patient lies on the back, with the knees elevated ; the pulse is small, wiry and rapid ; the temperature is elevated, 101°–103°, sometimes higher ; nausea and vomiting are common ; more or less tympanites is present ; the bowels are constipated ; there is frequently irritability of the bladder ; often menorrhagia.

Chronic peritonitis may exist and present scarcely any symptoms

save a dull pain in the pelvis; usually, there is vesical and rectal irritability, dyspareunia, leucorrhœa, and a disturbance of menstruation, especially menorrhagia.

Chronic peritonitis may follow the acute, or may begin as chronic.

Pelvic peritonitis is often characterized by exacerbations.

What are the physical signs of acute pelvic peritonitis?

The vagina is hot and dry; pressure in either fornix, or on the abdomen, is intensely painful; the bimanual is impracticable; the uterus, tubes and ovaries are usually bound fast; the slightest attempt to move them causes intense pain. The fornices may seem to be covered by a hard, flat roof, formed by a matting together of the pelvic contents, often compared to plaster-of-Paris poured into the pelvis and hardened; you may feel a tumor close to the uterus, consisting of serum or pus, roofed in by adhesions; the most common situation of this tumor is in the pouch of Douglas.

What are the common results of pelvic peritonitis?

Displacement of uterus, ovaries and tubes, the tubes being often distorted and stenosed by the traction of adhesions; as a result of these conditions we get disturbances of menstruation, sterility and ectopic gestation.

What is the prognosis of pelvic peritonitis?

Simple adhesive peritonitis often ends in complete recovery; displacement of the pelvic organs may remain, however, and give rise to symptoms. The prognosis of purulent peritonitis is grave.

What is the treatment of pelvic peritonitis?

In the acute form, keep the patient quiet in bed, give fluid diet, apply cold to the lower portion of the abdomen, either in the form of the ice-bag or cold-water coil. In some cases hot applications are more grateful to the patient; if there is great pain, give a little morphine; after a few days, move the bowels gently, as by calomel gr. j every hour for 3–4 doses, assisted, if necessary, by an enema. After the acute stage has passed use hot douches, and in chronic cases, iodine externally and per vaginam, and vaginal tampons of boroglyceride or ichthyol and glycerine. A wet towel, covered by a dry one for a protective, worn about the pelvis at night, is sometimes

of value in chronic peritonitis. Look after the general health by attention to fresh air, administering tonics, and regulating the bowels.

Pelvic Cellulitis.

What are the principal situations of the cellular tissue in the pelvis?

1. Between the abdominal wall and peritoneum, behind the pubes
2. In front of and behind the cervix.
3. In the broad ligaments.
4. In the utero-sacral ligaments.

What is the etiology of pelvic cellulitis?

The etiology of pelvic cellulitis may almost invariably be summed up in two words—traumatism and sepsis; the traumatism being, usually, labor, abortion, or operations on the cervix.

Pelvic cellulitis was formerly considered very common, but in the light of recent experience, gained by laparotomies, the "masses," "thickenings," etc., are most often found to be salpingitis and peritonitis.

In other words, pelvic cellulitis, although it does exist, is comparatively infrequent.

What is the pathology?

There is an exudation of serum, fibrin and white cells; this may resolve, it may form new connective tissue, cicatricial tissue, or it may, and often does, suppurate. If suppuration occurs, the pus may point above the pubes; this is especially common in puerperal cases. It frequently ruptures into the vagina, bladder or rectum, sometimes into the uterus; it occasionally makes its way through the sciatic or obturator foramen; rarely, it ruptures into the peritoneal cavity.

What are the symptoms of pelvic cellulitis?

The disease is usually ushered in by a rigor, which is often marked; the temperature rises, 103°–105°; the pulse is full and rapid; the pain is not very acute; nausea is occasionally present; vomiting is usually absent, unless peritonitis is a complication. If pus forms, septic symptoms become pronounced. There is often irritability of bladder and rectum.

Chronic cases may present few symptoms save a feeling of weight in the pelvis, irritability of bladder and rectum, and menorrhagia.

What are the physical signs?

Usually, there is a tense, elastic tumor bulging into the vagina, most commonly on the left side, pushing uterus over to the right; it is sensitive, but not acutely so. Sometimes the inflammatory process involves nearly all the connective tissue of the pelvis, and the exudation can be felt in the iliac fossæ and above the pubes. When pus forms you have the physical signs of an abscess—tenderness, fluctuation, etc.

From what should you differentiate pelvic cellulitis?

From—

a. Pelvic peritonitis.
b. Pelvic hæmatocele.
c. Fibroid tumor of uterus.
d. Impaction of fæces.
e. Ovarian tumor.
f. Salpingitis.

How would you differentiate pelvic cellulitis from pelvic peritonitis?

In many cases it is almost impossible to differentiate the two; they frequently complicate each other. The chief points of difference are these: Pelvic cellulitis almost never occurs except after labor, abortion, or operation on the cervix; pelvic peritonitis may arise from any cause of inflammation of the uterus or its adnexa, which may extend to the peritoneum. Pain and tenderness, as a rule, are less marked in cellulitis than in peritonitis. Cellulitis is more apt to bulge into the vagina than is peritonitis. Cellulitic deposits are more apt to suppurate than are peritonitic. Vomiting is less frequent in cellulitis than in peritonitis.

How would you differentiate pelvic cellulitis from pelvic hæmatocele?

Chiefly by the history of an hæmatocele, *i. e.*, sudden sharp pain, pallor, faintness, and the physical signs of a collection of fluid which afterward coagulates and hardens. The above symptoms of shock and hemorrhage are wanting in cellulitis.

How would you differentiate cellulitic or peritonitic deposits from fibroids of the uterus?

Cellulitic or peritonitic deposits vs.	*Fibroid tumors.*
History of acute inflammation.	Slow growth.
Pain and tenderness.	Insensitive.
Less plainly outlined.	Outlines more distinct.
Less intimately connected with the uterus.	Closely connected with the uterus.
Perhaps menorrhagia during the acute stage, then irregular menstruation.	Usually menorrhagia, gradually increasing till the menopause.

How would you differentiate impaction of fæces from pelvic peritonitis or cellulitis?

In impaction of fæces, the mass is sausage-shaped, has a doughy feel, is situated in the position of the rectum, and is less closely connected with the uterus than an exudation of peritonitis or cellulitis; it is not as tender on pressure, and gives no history of acute inflammation. The diagnosis is made certain by clearing out the rectum.

How would you differentiate a small ovarian tumor from pelvic peritonitis or cellulitis?

There are no signs of acute inflammation as in cellulitis or peritonitis; the ovarian cyst is usually fluctuating; its multilocular character can sometimes be felt. The menstrual disturbances common in peritonitis and cellulitis are usually absent in cases of ovarian cysts; an ovarian cyst gradually increases in size.

How would you differentiate pelvic cellulitis from salpingitis?

By a careful bimanual, in a case of salpingitis, you can generally map out an enlarged, tortuous tube, usually distended, extending from the side of the uterus to the region of the ovary; if distended with fluid, you may detect fluctuation. It does not bulge into the vagina as does cellulitis.

The history of the case is of value in the diagnosis.

What is the treatment of pelvic cellulitis?

1. Prophylactic :—

Strict cleanliness and antiseptic precautions during labor, abortion, operations, etc.

2. Abortive :—

Put patient to bed, apply cold to the lower portion of abdomen.

3. When exudation has occurred :—

Apply heat to the abdomen, administer hot-water vaginal douches, move bowels, and attend to the general health.

4. If the exudation suppurates :—

As soon as pus is detected, incise under antiseptic precautions and drain. The two most favorable sites for incision are through the vagina and through the abdominal wall just above Poupart's ligament. In doubtful cases it is sometimes advisable to open the abdomen in the median line, and then determine by the relations of the mass, the best mode of procedure. This, however, is rarely necessary.

Pelvic Hæmatocele and Hæmatoma.

Define, and give the pathology.

Pelvic hæmatocele is an effusion of blood into the cavity of the pelvic peritoneum.

Pelvic hæmatoma is an effusion of blood into the connective tissue of the pelvis beneath the peritoneum, usually between the folds of the broad ligaments.

In a pelvic hæmatocele, the effusion is usually into the pouch of Douglas; if this is closed by adhesions, or if the effusion is very large, the blood may flow over into the utero-vesical pouch. The former condition gives rise to the name retro-uterine, the latter to ante-uterine hæmatocele. The blood is at first fluid; it then slowly coagulates and is roofed in by peritonitic exudate binding together adjacent structures :—coils of intestine, omentum, uterus, etc. This blood mass, if small, may be absorbed; usually, however, it is due to a ruptured ectopic gestation sac or a tubal abortion and under these circumstances recurrent hemorrhages into the mass, sufficient to burst its limiting wall are common. Occasionally, apparently from proximity to the intestine, it suppurates.

What is the etiology of pelvic hæmatocele?

Formerly long lists of causes were given for this condition. We now know that in most cases it is due to a ruptured ectopic gestation sac or a tubal abortion. It is probable that exceptions to this rule occasionally occur, such as—

Rupture from traumatism of vascular peritonitic adhesions.
Oozing after removal of diseased tubes and ovaries.
Excessive hæmorrhage from the rupture of a Graafian follicle.
Rupture of an ovarian hæmatoma.

What is the etiology of pelvic hæmatoma?

Here again a rupture of an ectopic gestation sac is a very common cause. Other causes, however, are probably more frequent than in the case of pelvic hæmatocele, for varix of the broad ligament, due to various causes of venous congestion is common, and when such a varix exists, but a slight traumatism is needed for a blood effusion.

What are the symptoms of pelvic hæmatocele?

A sudden sharp pain, and symptoms of shock and hemorrhage. The face becomes pallid, the expression anxious; the pulse is rapid and feeble; temperature subnormal; surface covered with a cold perspiration: perhaps nausea and vomiting. Later if the patient survive, we have symptoms of peritonitis and of pressure, either from the effusion or the displaced uterus. The pain and tenderness continue for several days; there is usually painful defecation and dysuria; usually metrorrhagia is present. In a few days, if suppuration does not occur, the effusion diminishes in size and the symptoms abate. If suppuration occurs, septic symptoms appear.

The above are the symptoms of a well-marked case; where the effusion is small the symptoms may be much less severe.

How do the symptoms of pelvic hæmatoma compare with those of pelvic hæmatocele?

In pelvic hæmatoma there is, as a rule, less pain and less shock. If the effusion is large, however, there may be the symptoms of shock and hemorrhage.

What are the physical signs of pelvic hæmatocele?

At first no tumor is felt; only an indistinct sensation of fulness in the pouch of Douglas; as the blood coagulates and is roofed in by adhesions, one can feel a boggy tumor bulging downward in the posterior vaginal fornix and pushing the uterus forward.

What are the physical signs of pelvic hæmatoma?

In this case there is felt a distinct tumor even at first; it bulges

down on one side of and behind the cervix; pushes the uterus forward and to the opposite side; seems attached to the side of the pelvis and can be felt above Poupart's ligament when it has opened out the folds of the broad ligament and lifted up the peritoneum from the pelvis. A finger introduced into the rectum will usually detect a stricture.

What is the prognosis of pelvic hæmatocele?

The prognosis is usually that of ruptured ectopic gestation and will be discussed under that condition.

What is the prognosis of pelvic hæmatoma?

Usually good. If the effusion suppurates, the prognosis is less favorable. It may rupture into rectum, vagina, bladder, or rarely above the pelvic brim.

How would you differentiate pelvic hæmatocele from acute pelvic peritonitis?

Pelvic hæmatocele vs.	*Acute pelvic peritonitis.*
History of sudden, sharp pain, with symptoms of shock and hemorrhage.	Less sudden in onset; symptoms of shock and hemorrhage wanting.
Absence of acute inflammation at first.	Symptoms of acute inflammation at first.
Uterus usually displaced forward.	Uterus fixed, not markedly displaced.

How would you differentiate pelvic hæmatocele from a fibroid tumor of the uterus?

Pelvic hæmatocele vs.	*Fibroid tumor.*
History of sudden, sharp pain and symptoms of shock and hemorrhage.	Of slow growth; symptoms gradually developed.
Soon followed by signs of inflammation.	Absence of signs of inflammation.
Less intimately connected with the uterus.	More intimately connected with the uterus; moves with it.
Sensitive to pressure.	Insensitive to pressure.
Density less.	Density greater.

How would you differentiate pelvic hæmatocele from a retroflexed or retroverted uterus?

Pelvic hæmatocele vs.	*Retroflexed or retroverted uterus.*
Acute history of pain, shock and hemorrhage.	Usually a long history.
Fundus of uterus usually lies forward.	Fundus backward; absent in front.
Sensitive to pressure.	Less sensitive, unless surrounded by peritonitis.

How would you differentiate pelvic hæmatocele from an ovarian cyst?

Pelvic hæmatocele vs.	*Ovarian cyst.*
Acute history of pain, shock and hemorrhage.	History of slow growth, with few general symptoms.
More sensitive to pressure.	Less sensitive to pressure.
First elastic and soft, then hard.	Usually fluctuating throughout.

How would you differentiate pelvic hæmatocele from impacted fæces?

By the history, rectal examination, and thorough emptying of the rectum.

How would you differentiate pelvic hæmatocele from retro-uterine carcinoma?

Pelvic hæmatocele vs.	*Retro-uterine carcinoma.*
Acute history of pain, shock and hemorrhage.	History of a chronic disease.
Uterus usually pushed forward.	Uterus but little displaced.

How would you differentiate pelvic hæmatoma from pelvic cellulitis?

Pelvic hæmatoma vs.	*Pelvic cellulitis.*
History of sudden, sharp pain, perhaps symptoms of shock and hemorrhage.	History of labor, abortion, or operation on the cervix.
Signs of acute inflammation absent at first.	Signs of acute inflammation from the first.
Less sensitive.	More sensitive.

What is the treatment of pelvic hæmatoma?

Keep the patient quiet in bed: at first apply cold, later heat, both externally in the form of poultices and per vaginam by hot water douches. If suppuration occurs, open and drain through the vagina. If repeated hemorrhages are added to this hæmatoma two courses are open according to the size of the tumor. If the tumor is small and low in the pelvis, incise through the vagina, clean out clots, etc., and drain. If the tumor is large and extends high in the pelvis, it is probably better to open the abdomen and govern the treatment by the condition found.

The treatment of pelvic hæmatocele will be considered under ectopic gestation.

MENSTRUATION.

Define.

Menstruation is a periodical series of phenomena, the most marked of which is a discharge of blood from the uterine mucous membrane, beginning, on an average, in this country, at fourteen, and recurring monthly till forty-five. The relation of menstruation to ovulation is still unsettled. As a rule they are simultaneously present or absent, but either may be present for a short time without the other.

Describe the factors which influence the onset of menstruation; what is the average frequency and duration of each period?

In temperate climates, menstruation usually appears at 13–15 years; it is earlier in warmer climates, later in cooler; it appears in girls who live an indoor, city life, earlier than in the country. The periods normally appear every 28 days, but in this there are great variations; some women in perfect health menstruate every 3 weeks, some only every 5 weeks.

The average duration of each period is 3–4 days, but this varies between 2 and 8. The discharge of blood is usually slight at first, reaches maximum on the second or third day, then gradually diminishes.

Disorders of Menstruation.

Amenorrhœa.

Define.

Amenorrhœa is the absence of menstruation between puberty and the menopause. It is the normal condition during pregnancy and lactation. Menstruation may be present, but "concealed," due to atresia of the lower part of the genital tract. It may be divided into:—

a. Emansio mensium—

Where menstruation has never appeared.

b. Suppresio mensium—

Where menstruation has appeared, but fails to reappear.

What is the etiology of amenorrhœa?

The most frequent cause is anæmia, especially that form called chlorosis. Other causes are phthisis, or other debilitating diseases; acute diseases at puberty; non-development of the generative organs; atrophy of the generative organs; increasing obesity; removal of ovaries and tubes by operation.

What are the symptoms?

Amenorrhœa is itself more a symptom than a disease, and the symptoms which usually accompany amenorrhœa are those of the disease which causes it—most frequently anæmia or phthisis. Thus, from anæmia we have:—

Pallor.
Dyspnœa and palpitation of the heart on exertion.
Depraved appetite.
Constipation.
Headache.
Œdema.
Murmur at the base of the heart.
Neuralgic pains.
Hysteria.

From phthisis we get the regular symptoms of cough, emaciation and night sweats.

What is the prognosis?

When associated with simple anæmia the prognosis is good. When due to non-development of the generative organs the amenorrhœa usually continues. When associated with phthisis or other wasting disease, the prognosis is that of the disease.

What is the treatment of amenorrhœa?

a. When due to anæmia:—

Some form of iron, as Blaud's pills; oxygen; nourishing food; fresh air; regulation of the bowels, and attention to the mode of life.

b. When due to imperfect, or non-development of the generative organs:—

Determine, under anæsthesia, whether ovaries are present or not; if absent, do not attempt to induce menstruation. If the ovaries are present, besides attention to the general health, the following methods may be employed:—

Hot water vaginal douches;
Boro-glyceride tampons;
Electricity to uterus and over ovaries.

c. When associated with phthisis, or other wasting disease, the treatment is that of the associated disease.

In cases of acute suppressio-mensium, due to exposure to cold, etc., hot mustard foot baths, hot applications to the pelvic region and diaphoretics internally, may be used with safety and advantage.

Vicarious Menstruation.

Describe.

Vicarious menstruation is a periodical discharge of blood from some part of the body other than the interior of the uterus. It may occur with either amenorrhœa or scanty menstruation; it usually appears at about the time of the regular flow. It may come from almost any mucous membrane: from the nose, mouth, etc.; it may also come from the nipple or from an open sore; it is usually due to a watery condition of the blood and a poor condition of the blood-vessels. Direct treatment is usually not required.

Menorrhagia and Metrorrhagia.

Define.

Menorrhagia is a prolonged or excessive menstrual flow.

Metrorrhagia is "uterine hemorrhage occurring independently of the menses."

What is the etiology?

Menorrhagia and metrorrhagia may be produced by causes acting at a distance, or local, in or about the uterus itself. Acting at a distance are :—

1. Obstructed general circulation from disease of heart, lungs or liver.
2. Low condition of blood and vessels in certain wasting diseases.

Acting about the uterus are :—

1. Tumors.
2. Ectopic Gestation.
3. Disease of tubes or ovaries.

The most common causes are situated in the uterus itself, and among them are the following :—

1. Subinvolution of the uterus ;
2. Retained secundines ;
3. Submucous, or interstitial fibroids ;
4. Polypi ;
5. Carcinoma ;
6. Fungous granulations of the endometrium.

The last is the most common cause of all.

What is the treatment of menorrhagia and metrorrhagia?

When due to causes acting outside of the uterus, the treatment is that of these causes ; at the same time, there will often be found fungous granulations of the endometrium which magnify the influence of the distant causes ; unless otherwise contraindicated, these fungosities need to be removed by the curette under antiseptic precautions ; the uterine cavity is then washed out, and an application of iodine or carbolic acid or a mixture of the two may then be made to the endometrium. In mild cases of menorrhagia or metrorrhagia ergot and hydrastis canadensis are of value even without the use of the curette, and in nearly all except malignant cases after curetting.

Diseases of the tubes and ovaries and ectopic gestation require their own treatment. Fibroids may demand removal of the tumor or hysterectomy. Polypi require removal. Carcinoma indicates hysterectomy. Fungous endometritis demands curetting as above.

Dysmenorrhœa.

Define.

"Dysmenorrhœa may be defined as the occurrence of pain just before, during or after the menstrual period" (Hart and Barbour).

What are the varieties of dysmenorrhœa?

The following varieties are mentioned, but seldom distinctly differentiated :—

1. Obstructive;
2. Congestive;
3. Neuralgic;
4. Ovarian;
5. Membranous.

Obstructive Dysmenorrhœa.

What is the etiology?

Both the etiology and pathology of the different varieties of dysmenorrhœa are still far from settled, but the conditions usually associated with obstructive dysmenorrhœa are :—

a. Flexions of the uterus;
b. Stenosis of os externum, os internum, or the whole cervical canal;
c. Polypi;
d. Fibroids distorting uterine canal;
e. Long, conical cervix;
f. Spasmodic contraction of os internum.

What are the symptoms?

Intermittent, cramp-like pains, accompanying the expulsion of blood clots which have formed above the obstruction; this expulsion is followed by relief. A sound passed between the periods usually shows hyperæsthesia of the internal os.

What is the treatment?

During the intermenstrual period dilate the cervical canal with one of the dilators of the glove-stretcher variety. If there seems to be any endometritis present, curette the uterus and wash it out. Pack the cavity with iodoform gauze, and unless the pain is severe leave it for forty-eight hours; this will maintain the dilatation for quite a period. In order to prevent future recontraction, the occasional introduction of graduated sounds is of value. All this must be done under strict asepsis. The use of intra-uterine stems had better be abandoned. For the temporary relief of the several varieties of dysmenorrhœa the preparations of viburnum are of value.

Congestive Dysmenorrhœa.

What is the etiology?

"Congestive dysmenorrhœa depends upon an advance of the menstrual congestion beyond the physiological limits" (Reeve).

The conditions associated with congestive dysmenorrhœa are the following:—

a. Exposure to cold;
b. Defective general circulation;
c. Metritis;
d. Endometritis;
e. Displacements of the uterus;
f. Pelvic tumors;
g. Pelvic peritonitis.

What are the symptoms?

Between the periods there are usually symptoms of pelvic trouble, or defective general circulation.

Just before the flow begins, there appear feelings of weight and heat in back and pelvis, headache, flushing of the face, and some rise of temperature; the pulse is rapid. The symptoms are usually relieved by a free flow.

What is the treatment?

a. During the attack—

1. Hot mustard foot-baths;
2. Hot sitz-baths;
3. Diaphoretics, such as Dover's powder;
4. Hot pelvic applications.

b. During the intermenstrual periods—

1. Seek to remove the cause;
2. Scarify cervix occasionally;
3. Employ glycerine tampons;
4. Avoid excessive coitus and exertion.

Just before the flow begins, use hot-water vaginal douches.

Neuralgic Dysmenorrhœa.

What is the etiology?

This frequently occurs in combination with some of the other forms of dysmenorrhœa, especially the congestive; it is most often associated with an indolent, indoor life, anæmia, malnutrition, chronic malarial disease or hysteria. Sometimes no cause can be assigned.

What are the symptoms?

Pain, sometimes referred to uterus, sometimes to ovaries, sometimes elsewhere; it changes its situation; is often shooting in character; usually begins a little before the flow; is sometimes relieved by a free flow. Between the periods, no pathological changes can be detected in the pelvic organs, but patient suffers from neuralgia elsewhere—facial, intercostal, etc.

What is the treatment?

Attention to the mode of life; fresh air; exercise; tonics, especially iron, arsenic and quinine; at the onset of the pelvic pains employ hot sitz-baths and hot-water vaginal douches, and give internally such anti-neuralgics as phenacetin.

Ovarian Dysmenorrhœa.

What is the etiology?

This is applied to a class of cases associated with disease of the ovaries, but the etiology is far from settled, and the class not distinct.

What are the symptoms?

Between the periods there is pain and tenderness over the region of the ovary, increased by exercise, defecation and coitus; these symptoms are increased at the menstrual periods.

Membranous Dysmenorrhœa.

Describe.

"Membranous dysmenorrhœa is characterized by the expulsion at the menstrual periods of organized membranes either as a whole or in pieces." (Reeve.)

Fig. 13.

Sketch of a Dysmenorrhœal Membrane as seen under Water (Sir J. Y. Simpson).

What is the etiology and pathology?

These are both matters of dispute, but we usually find in these cases chronic endometritis and poor general health. The inner surface of the membrane is smooth and shows the openings of the utricular glands; its external surface is rough and shaggy (see Fig. 13). Microscopically it resembles the decidual membrane occurring in pregnancy.

According to Hart and Barbour, "It is of the greatest importance

to remember that it is not a product of conception, and should not be mistaken for an early abortion." It is composed of the superficial layer of the endometrium, with increased connective tissue; blood accumulates under it and dissects it off.

What are the symptoms?

Severe colicky pain, usually recurring at each period; the flow is often intermittent; thus the symptoms resemble those of obstructive dysmenorrhœa. The course is usually protracted.

How would you differentiate membranous dysmenorrhœa from an early abortion?

By the absence of chorionic villi and by the repeated occurrence

What is the treatment?

a. Between the periods—

Dilate the cervix, curette the uterine canal, and apply to the endometrium iodized phenol, pure carbolic, or tincture of iodine.

b. During the menstrual period—

Use hot baths, hot applications to the pelvis, and diaphoretics.

Malformations of the Vagina.

What are the important varieties?

a. Atresia vaginæ;
b. Double vagina;
c. Absence of vagina.
d. Stenosis of vagina.

Atresia Vaginæ.

Give the varieties and etiology.

Atresia of the vagina may be either at the hymen, forming atresia hymenalis, or higher up in the vagina, forming atresia vaginalis.

Etiology.—Atresia hymenalis is usually congenital, from maldevelopment. Atresia vaginalis is either congenital, or may be acquired from cicatrization following—

a. Sloughing incident to parturition;
b. Adhesive vaginitis;
c. Traumatism;
d. Caustics.

What are the symptoms of atresia vaginæ?

They are dependent on the accumulation of the menstrual blood, hence in congenital cases they are absent till puberty. The subjective symptoms of menstruation come on, but there is no appearance of blood; at the next period the subjective symptoms are repeated. The periods then usually come more frequently, and soon a tumor forms. If the atresia is at the hymen, the latter bulges, and the vagina is distended with blood, forming a hæmato-colpos.

In atresia hymenalis the cervix is usually not dilated; in atresia vaginalis the dilatation may extend to the uterus and tubes.

If the atresia is acquired, of course there will be no symptoms till the menstrual blood is retained.

What are the results of atresia hymenalis if unrelieved by operation?

If the hymen is thin, it may rupture; if thick, the vagina may rupture; after rupture, septicæmia may occur.

What are the results of atresia vaginalis?

The vagina may rupture.

The uterus and tubes may become distended, forming hæmatometra or hæmato-salpinx, and may rupture.

The atresia may rupture.

After rupture, septicæmia may occur.

Where else in the genital tract than in the vagina may atresia occur? Give the etiology and symptoms.

Atresia may occur at the cervix.

Atresia of the cervix may be congenital, or acquired from cicatrization following parturition, the use of caustics, or from a too close trachelorrhaphy. Symptoms appear when the menstrual blood accumulates behind the atresia, and resemble those of atresia vaginæ. The amenorrhœa and enlargement of the uterus may make one suspect pregnancy.

What are the results of atresia of the cervix if unrelieved by operation?

If it is present during menstrual life, the uterus and tubes become distended, and are liable to rupture, with the danger of peritonitis and death. If it occurs for the first time after the menopause, it usually causes no trouble.

What is the character of the retained fluid?

During menstrual life the blood is of a brownish, chocolate color; it is grumous and treacle-like in consistency, kept from clotting by the mucus.

After the menopause, the retained fluid is honey-like.

What is the treatment of atresia of the genital tract with retention of the menstrual blood?

Aspirate slowly; under strict antisepsis incise the obstruction, and maintain the opening by iodoform gauze or a rigid drainage-tube.

What are the dangers of rapid evacuation of a hæmatometra?

The tubes are probably distended, and have formed adhesions; the rapid collapse of the uterus would tend to tear the tubes from their adhesions, with the danger of rupture of the tubes, and peritonitis.

Stenosis of Vagina.

Give its cause and describe.

It may be acquired from cicatrization of the vagina or be congenital. The congenital stenosis is not infrequent just in front of the cervix. It interferes with coitus and labor and gives rise to vaginitis by interfering with the drainage of the upper part of the vagina.

Malformations of the Uterus.

What are the principal varieties?

1. Rudimentary uterus;
2. Uterus bipartitus;
3. Uterus unicornis;
4. Uterus bicornis;
5. Uterus didelphys;
6. Uterus septus;
7. Infantile uterus;
8. Congenital atrophy of the uterus;
9. Complete absence of the uterus, very rare.

Describe the rudimentary uterus.

In this case (see Fig. 14) "the uterus is represented by a band of muscular fibre and connective tissue on the posterior wall of the bladder." (Hart and Barbour.)

Describe the uterus bipartitus.

In the uterus bipartitus (see Fig. 15) the rudimentary horns are present, and are either hollow or solid and cord-like; they are connected to each other and to the vagina by the cervix, which is represented by a fibrous band. The ovaries, breasts and external genitals may be well developed.

Describe the uterus unicornis.

The body of the uterus in this variety (see Fig. 16) is long and narrow, and is directed to one side; its fundus has attached to it one Fallopian tube and ovary; on the opposite side of the body is seen the representative of the other horn, which is either solid or hollow; connected with this, and separated from it by the attachment of the round ligament, are the tube and ovary of that side.

Describe the uterus bicornis.

In this form (see Fig. 17) the division into two horns is distinctly visible externally; the division is usually seen also in the interior of the uterus on section.

What is the uterus didelphys?

Here the two halves of the uterus are separated throughout (see Fig. 18). This condition is very rare.

Describe the uterus septus.

Here the division is entirely internal (see Fig. 19); beginning at the fundus, it extends a variable distance toward the os externum, sometimes reaching it. There is no indication of the division from the outside.

What is an infantile uterus?

In this condition (see Fig. 20) the cervix is 2–3 times longer than the body, the relation of cervix to body remaining as at birth. The uterus as a whole is smaller than normal.

What is meant by congenital atrophy of the uterus?

The relative lengths of cervix and body (see Fig. 21) conform to those of a virgin uterus, but the whole uterus is atrophied.

FIG. 14.

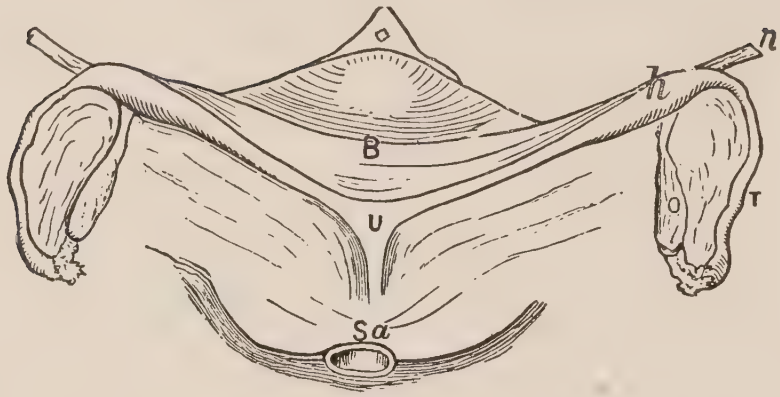

Rudimentary Uterus (Veit). *Sa*, sacrum; *U*, solid rudiment of uterus; *h*, rudimentary horn; *B*, bladder; *O*, ovary; *T*, Fallopian tube; *r* round ligament.

FIG. 15.

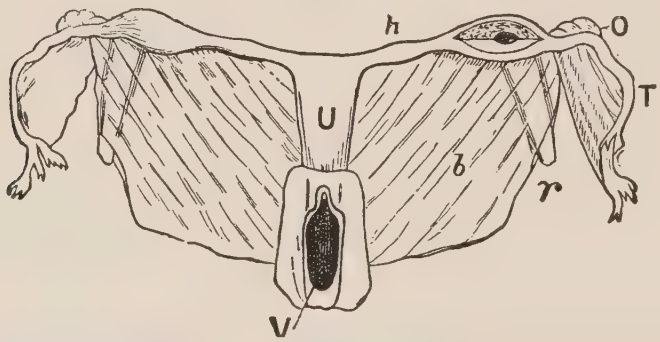

Uterus Bipartitus (Rokitansky). *V*, vagina; *U*, uterus; *h*, rudimentary horn; *O*, ovary; *T*, tube; *r*, round ligament; *b*, broad ligament.

FIG. 16.

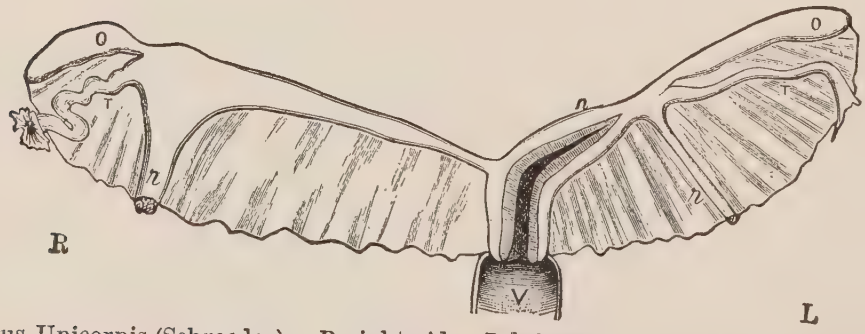

Uterus Unicornis (Schroeder). *R*, right side; *L*, left side. The left horn (*h*) is well developed and communicates with the uterine cavity. The right horn is in the form of an elongated band; its point of connection with the Fallopian tube is indicated by the insertion of the round ligament, which is hypertrophied. Other letters as in preceding diagrams.

FIG. 17.

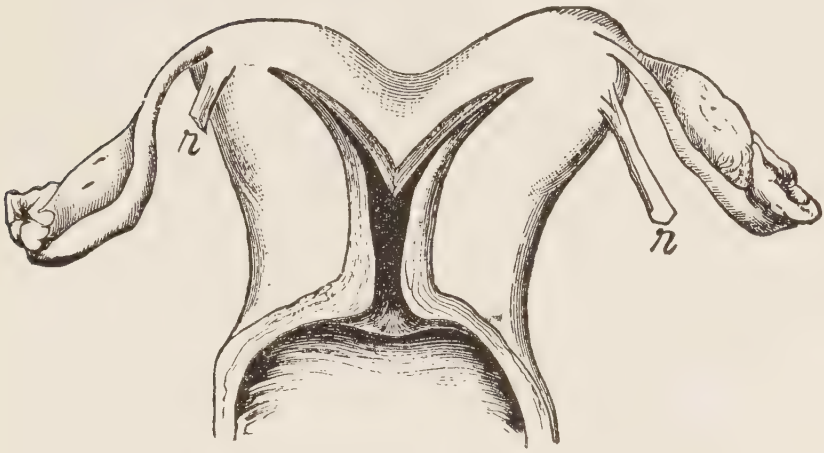

Uterus Bicornis Unicollis (Schroeder). *r*, round ligament.

FIG. 18.

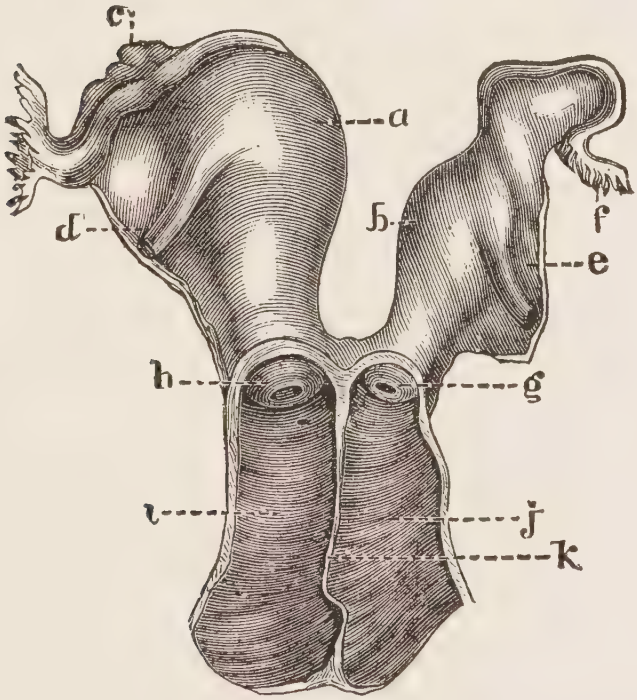

Uterus Didelphys. *a*, right cavity; *b*, left cavity; *c*, right ovary; *d*, right round ligament; *e*, left round ligament; *f*, left tube; *g*, left vaginal portion; *h*, right vaginal portion; *i*, right vagina; *j*, left vagina; *k*, partition between the two vaginæ. (From De Sinety, after Ollivier.)

FIG. 19.

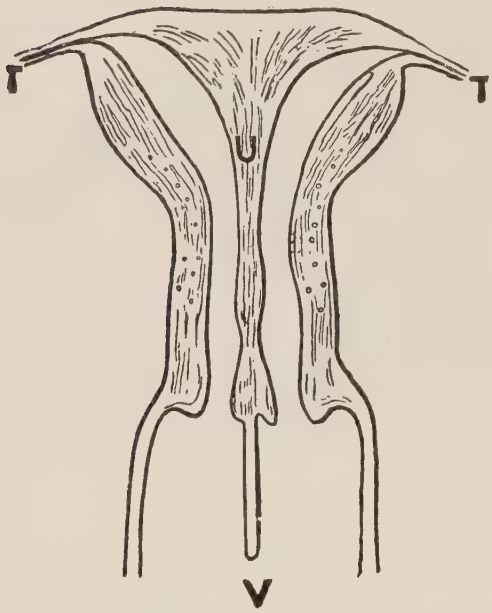

Uterus Septus in Vertical Transverse Section (Kussmaul). *U* (uterus), placed on septum which divides cavity into two lateral portions; *T*, Fallopian tubes; *V*, vagina divided into lateral cavities by prolongation of septum downward.

FIG. 20.

Infantile Uterus (Schroeder).

FIG. 21.

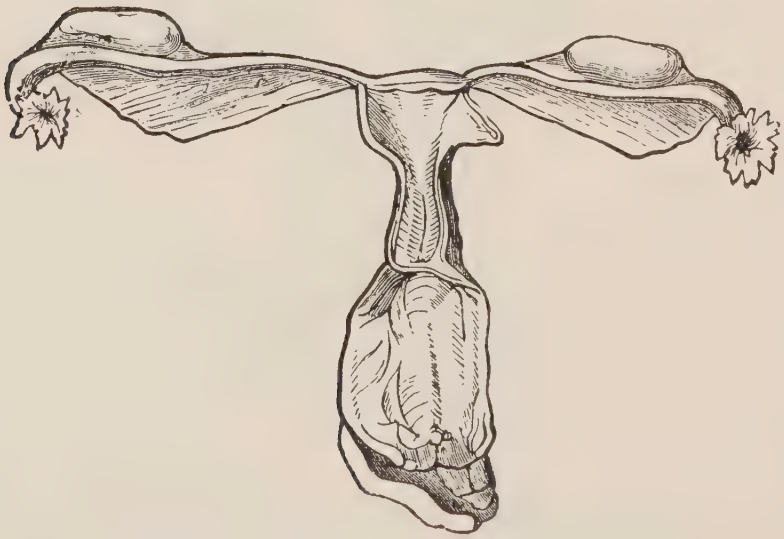

Primary Atrophy of the Uterus (Virchow).

What is the occurrence of complete absence of the uterus?

It is very rare indeed, and can only be ascertained by a post-mortem examination. Many cases of supposed absence of the uterus are proved, on autopsy, to be cases of rudimentary uterus.

What are the importance and danger of uterine malformations?

Pregnancy in such cases may endanger the patient's life. The diagnosis is difficult. Menstruation may occur from one half and pregnancy be present in the other. The pregnant cornu may be mistaken for a tumor or it may rupture with symptoms like those of ectopic gestation.

Displacements of the Uterus.

What do we mean by a displacement of the uterus in a clinical sense?

"Changes in the position of the uterus only become displacements, in the clinical sense, when they are more or less stable. Limitation or hindrance of the normal movements of the uterus is a main characteristic of its displacements." (Schultze.)

What are the principal displacements of the uterus?

a. Anteversion;
b. Anteflexion;
c. Retroversion;
d. Retroflexion;
e. Prolapse.

What is the difference between a "version" and a "flexion?"

In a "version" the canals of the cervix and body are in the same straight line; in a "flexion" they make an angle with each other.

Anteversion.

Discuss briefly.

The uterus is sometimes fixed in a position of anteversion owing to the pressure of encysted fluids, tumors, inflammatory masses or peritoneal adhesions. The symptoms are those of the causal condition. The anteversion, *per se*, gives rise to no symptoms, hence it is not usually considered among uterine displacements.

Anteflexion.

What is the pathology?

In anteflexion the body of the uterus is bent forward on the cervix (see Fig. 22); in order for this to be pathological, there must be rigidity at the point of flexion.

What is the etiology?

It may be congenital (puerile, Schultze) or acquired.

The most common causes of the latter are a metritis occurring in a flexible uterus, or an inflammatory process occurring in the utero-sacral ligaments, drawing the upper portion of the cervix upward

Fig. 22.

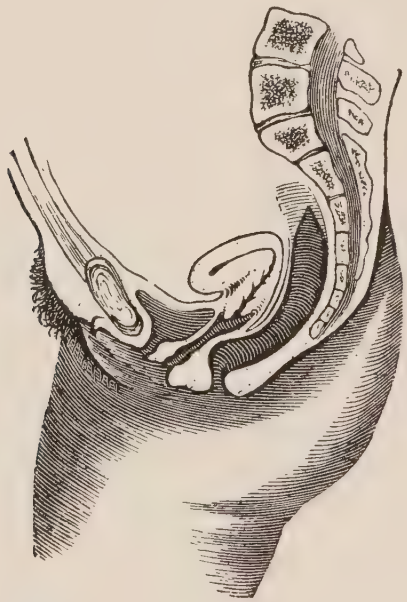

Anteflexion of the Uterus (Schroeder).

and backward. Bandl thinks cervical catarrh the first cause, extending to the cervical tissue, and then to the cellular tissue in the utero-sacral ligament.

It is sometimes caused by the adhesions of peritonitis drawing the upper portion of the cervix backward.

What are the symptoms?

a. Dysmenorrhœa;

b. Sterility;

c. Disturbance of bladder functions—frequent micturition;

d. Leucorrhœa;

e. Other symptoms are those of the accompanying inflammation.

What are the physical signs?

The cervix lies rather high; the os is directed downward and forward; as you pass the finger up along the anterior wall of the cervix, it runs into a marked angle between cervix and body. The body can be felt lying in front of the cervix, just above the anterior vaginal wall. The cervix is often long and the os small. The sterility is more dependent upon the long cervix plugged with mucus than any actual stenosis of the internal os. The uterus is sometimes both anteflexed and retroverted.

From what must you differentiate an anteflexion?

From—1. A fibroid tumor in the anterior wall of the uterus;
2. An inflammatory deposit in front of the cervix.

How would you differentiate an anteflexed uterus from a fibroid tumor in the anterior wall?

In an anteflexion you cannot feel the fundus elsewhere, and a sound passes when sharply curved into the body felt in front of the cervix.

In a fibroid in the anterior wall (see Fig. 23) the sound does not pass into the body felt in front of the cervix, but behind it, and the fundus can be felt above and behind the fibroid.

FIG. 23.

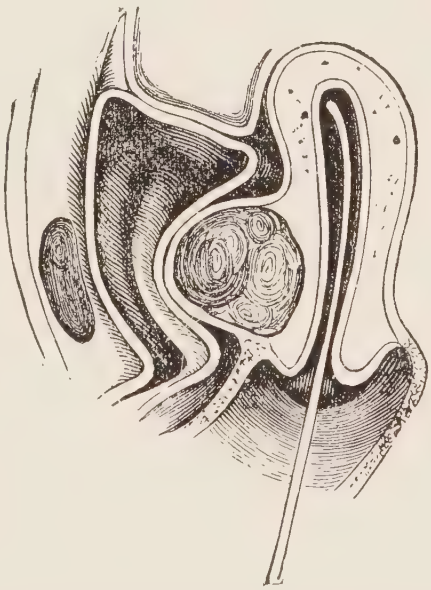

Sound passed to show that a Fibroid of the Anterior Wall is not an Anteflexion (Leblond).

How would you differentiate an inflammatory deposit from an anteflexion?

The former is comparatively rare, but when present is usually more sensitive than an anteflexion; in the case of an inflammatory deposit in front of the cervix, a careful bimanual examination will usually show the fundus elsewhere.

During the acute, inflammatory period the sound is contraindicated.

What is the treatment of anteflexion?

First treat all existing pelvic inflammation by means of hot-water douches, counter-irritation and glycerine tampons. When all inflammatory symptoms have subsided, dilate the cervix, under antiseptic precautions, with one of the glove-stretcher dilators, and pack the cavity with iodoform gauze leaving it for forty-eight hours. Maintain the dilatation by the introduction of the graduated hard dilators, or sounds, once or twice a month for two or three months.

Retroversion and Retroflexion.

Define.

"Retroversion may be defined as the permanent dislocation backward of the fundus uteri, when the form of the uterus is such that axis of body and axis of cervix are identical. Retroflexion denotes the permanent backward dislocation of the fundus uteri, with simultaneous flexion of the uterus over the posterior surface." (Harrison.)

What is the etiology and pathology?

Retroversion (see Fig. 24) may exist by itself, but with retroflexion there is always more or less retroversion. Usually the uterus is first retroverted, and then intra-abdominal pressure continuing, if the uterus is flexible, the fundus is pushed backward and downward. The combination of the two is thus most common, and is described as retroversio-flexio (see Fig. 25). Retroversio-flexio is most frequent in multiparæ following parturition, where the ligaments are lax and patient lies on the back, and especially if the patient rises before involution has occurred. It may occur, however, in nulliparæ or virgins, from severe blows, falls, lifting, straining, etc.; also from inflammatory adhesions, drawing the uterus backward.

The most common agent in pushing a movable uterus behind the perpendicular is distention of the bladder; intra-abdominal pressure may then act on the anterior surface of the uterus. Relaxation of the utero-sacral ligaments, and thickening and shortening of the utero-vesical, favor retroversio-flexio.

Pathologically, we usually find the body of the uterus congested and enlarged, its mucosa hyperplastic, and more or less rigidity at the junction of cervix and body, from development of fibrous tissue.

What are the symptoms?

1. More or less constant pain in the back;
2. Symptoms of pelvic inflammation;
3. Constipation;
4. Irritability of the bladder;
5. Leucorrhœa;
6. Menorrhagia;
7. Dysmenorrhœa, especially when flexion is marked;
8. Abortion;
9. Sterility;
10. Reflex neuroses.

Fig. 24.

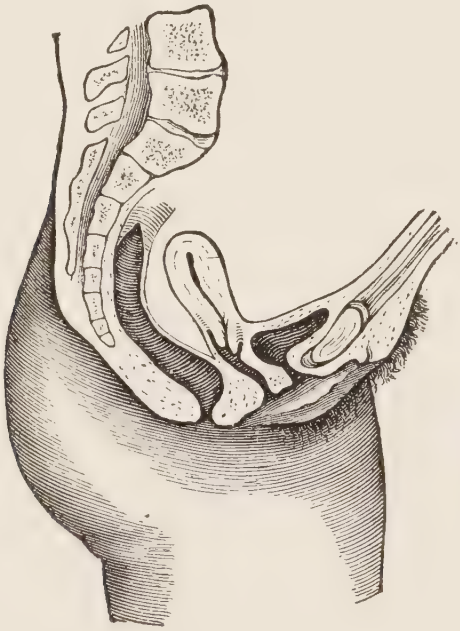

Retroversion of the Uterus (Schroeder.)

What are the physical signs?

On making the bimanual examination, you find the cervix nearer the vulva than normal, the fundus absent in front, and the os pointing more or less forward; on running the vaginal fingers along the posterior wall of the cervix, you find a body which, in a retroversion, continues the line of this wall, in a retroflexion makes an angle with it. This body moves as a part of the uterus; the sound passes into it.

From what must you differentiate retroversio-flexio?

1. Fibroid tumor on posterior wall of the uterus;
2. Fæces in the rectum;
3. Inflammatory deposits;
4. Prolapsed ovary or small ovarian tumor.

How would you differentiate retroversio-flexio from a fibroid on the posterior wall?

Make a careful bimanual examination. In case of a backward displacement of the uterus, we find an absence of the fundus in front, the cervix points more or less forward, and the sound, when introduced, goes backward.

Fig. 25.

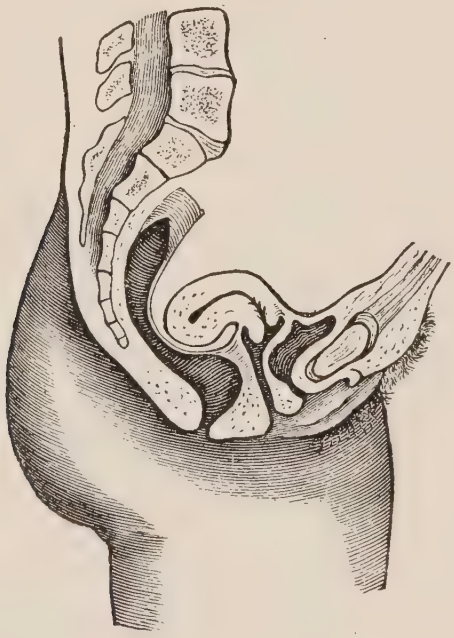

Retroversio-flexio.

In case of a fibroid on the posterior wall, the fundus may be felt in front of it, and the sound passes forward. The tumor may feel more irregular and harder than the uterus.

How would you differentiate the fundus uteri from fæces in the rectum?

On bimanual examination, the fundus can often be felt forward, and the sound passes forward; the fæces have a more doughy feel

than the uterus; if doubt exists, always empty the rectum before making a diagnosis.

How would you differentiate the fundus uteri from inflammatory deposits in the pouch of Douglas?

During the stage of acute inflammation this may be very difficult, as the sound is then contraindicated. Finding the fundus in front is the chief element in the diagnosis.

When acute inflammation has subsided, introduction of the sound will give great assistance.

How would you differentiate the fundus uteri from a prolapsed ovary or small ovarian tumor?

By making a careful bimanual examination, the uterus is found lying in front of the prolapsed ovary or tumor. Assistance may be given by the use of the sound, or drawing down the cervix with a volsella.

What are the indications in the treatment of retroversio-flexio?

1. To treat the pelvic peritonitis or cellulitis, if present, according to the regular methods;
2. To replace the uterus;
3. To retain it in place.

What are the methods of replacing a retroverted or retroflexed uterus when movable?

1. Place the patient in Sims' position; introduce index and middle fingers of the right hand into the posterior fornix vaginæ; have patient breathe deeply and slowly; during an expiration, raise the body of the uterus with the backs of the vaginal fingers till it passes the promontory of the sacrum, then transfer one or both fingers to the front of the cervix, and push that backward; this throws the fundus forward.

2. Another method is to replace the uterus while patient is in the dorsal position, by means of the bimanual, either vagino-abdominal or recto-abdominal. In this method the body of the uterus is raised by the fingers in the vagina or rectum until it can be grasped by the external hand, when it is then brought forward. In some cases this

operation is facilitated by first grasping the cervix with a volsella and pulling it downward in the axis of the vagina, thus straightening the uterine canal, making the fundus easier to reach by the examining finger and easier to lift above the sacral promontory.

3. When the body of the uterus is very sensitive, so that pressure by the fingers is very painful, the uterus may be replaced by means of the sound, as follows: Introduce the sound with the concavity backward; then make the handle describe an arc of a circle from behind forward; then slowly depress the handle toward the perineum; this throws the uterus forward.

4. To replace the gravid uterus, the following method is sometimes employed: Place patient in the genu-pectoral position; draw down cervix with the volsella, and press fundus uteri toward the bladder, with the finger in the rectum.

When the uterus in a retroversio-flexio is rigid at the angle of flexion, we do not expect to remove the flexion, but only to correct the version.

What are the methods of replacing a retroverted or retroflexed uterus when fixed by adhesions?

If signs of pelvic inflammation are present, treat the inflammation by hot douches, sitz-baths, wet pelvic packs, attention to the bowels, etc. When the inflammation has subsided, the uterus may gradually be replaced by cautious manipulation and stretching of the adhesions, and gentle attempts at raising the uterus, a few moments at a sitting, with the fingers in the posterior fornix vaginæ; after the manipulation insert a tampon, to be worn for twenty-four hours. At first the tampons are to be pressed firmly into the posterior fornix to exert an upward pressure on the fundus. Later, when the fundus can be nearly replaced, put the tampon in the anterior fornix to press the cervix backward and thus maintain the reposition already accomplished. The manipulations may be assisted by hot-water vaginal douches between the sittings. It is well to have the patient assume the knee-chest position once or twice daily.

Schultze's method of forcible reposition consists in placing the patient under anæsthesia, in the lithotomy position, inserting index and middle fingers of left hand high up into the rectum, and with these fingers forcibly, but gradually, elevating the fundus uteri and breaking up the adhesions; the right hand is placed on the abdo-

men, and as the uterus is elevated, it is grasped by this external hand and brought forward.

This method is rarely advisable.

What are the means for retaining the uterus in place after reposition?

1. Pessaries;
2. Operative procedures.

Pessaries.

What are the varieties in most common use?

1. The Albert Smith;
2. The Emmet;
3. The Thomas.

Describe them.

They are usually made of hard rubber; the Thomas pessary, however, is often made of soft rubber.

The Albert Smith (see Fig. 26) is a modification of the Hodge pessary; its anterior extremity is narrow, the posterior broad; the posterior extremity curves upward behind the cervix, the anterior downward away from the urethra.

The Emmet pessary is usually made of a larger bar than the Albert Smith, and the curve is much flattened.

The Thomas (see Fig. 27) is long, narrow, and has its posterior bar much enlarged.

How does a retroversion pessary act?

Not by pushing up the body or fundus, but by making the posterior vaginal wall tense, thus drawing the cervix backward, and in this way throwing the fundus forward.

What are the contraindications to the use of a pessary?

A pessary should not be introduced till all pelvic inflammation has subsided, and, as a rule, not until the uterus can be well brought forward; "but occasionally, when the uterus is elevated to about the promontory, the pessary may be applied."

What is the proper position of a retroversion pessary after introduction?

The broader extremity should lie behind the cervix and curve upward; the narrow in front and curve downward.

How would you introduce one of these retroversion pessaries?

They may be introduced with patient either in the dorsal or in Sims' position, preferably in the latter, and in the following manner: Standing at the side of the table, near the buttocks of the patient, separate the labia a little with the fingers of the left hand; taking the pessary by the smaller end with the thumb and index and middle fingers of the right hand, introduce it between the labia, with the breadth of the pessary in the line of the labia (see Fig. 28); depress the perineum with the pessary as you introduce it about half way,

Fig. 26.



Albert Smith Pessary.

Fig. 27.

Thomas Pessary.

then rotate, so that the breadth of the pessary lies at right angles to the labia; now grasp the external portion of the pessary with the left hand; pass the index finger or index and middle fingers of the right hand in front of the posterior bar (see Fig. 29) and carry the pessary along the posterior vaginal wall, being careful that it does not slip up in front of the cervix.

What are the precautions to be observed in the employment of a pessary?

A patient after the introduction of a pessary should be made to walk a little about the room, then to sit on a chair and cross one knee over the other, to ascertain if the pessary causes pain; if it does, it should not be kept in. A patient should always be told, on

leaving, that if the pessary causes her pain, she must introduce her finger and remove it. She should be seen in a few days after its introduction, to ascertain if the pessary is in position and is holding the uterus in place. If one is not able to insert the finger between the pessary and vaginal wall the pessary is too large and may cause

Fig. 28.

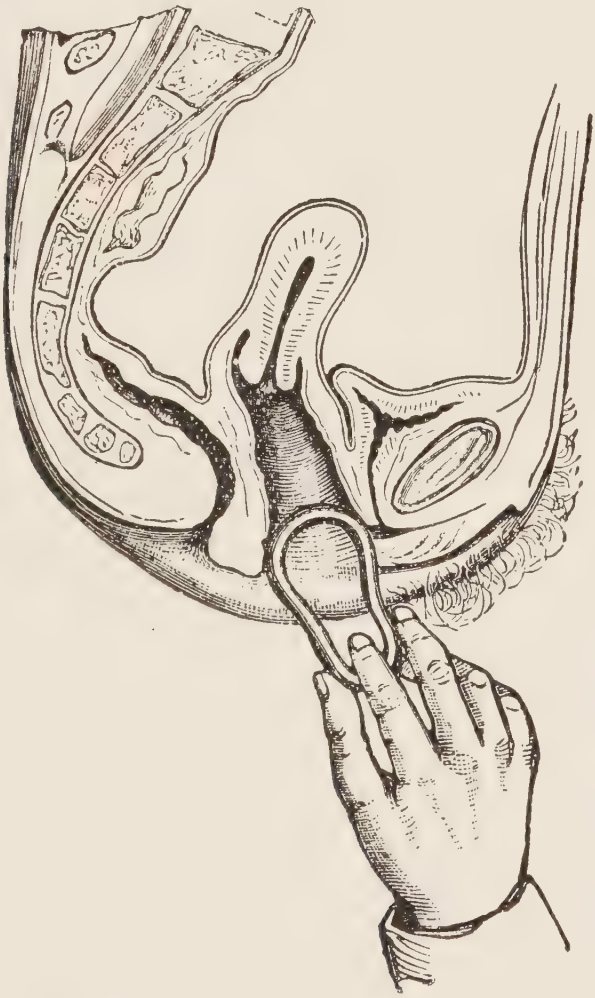

Introduction of Pessary, First Stage (Hart and Barbour).

ulceration. The pessary should be removed and cleaned as often as once a month; in the meantime the patient should be instructed to use a vaginal douche for cleanliness two to three times a week. Always before re-inserting the pessary examine the posterior fornix through a speculum to see that no pressure-sore is forming.

What are the operative procedures for holding a retroverted uterus in place after reposition?

a. Alexander's operation; *b.* Hysterorrhaphy, or ventral fixation; *c.* Intra-abdominal shortening of the round ligaments.

Describe briefly Alexander's operation.

Alexander's operation for shortening the round ligaments is performed as follows: The skin about the pubes is shaved and prepared

FIG. 29.

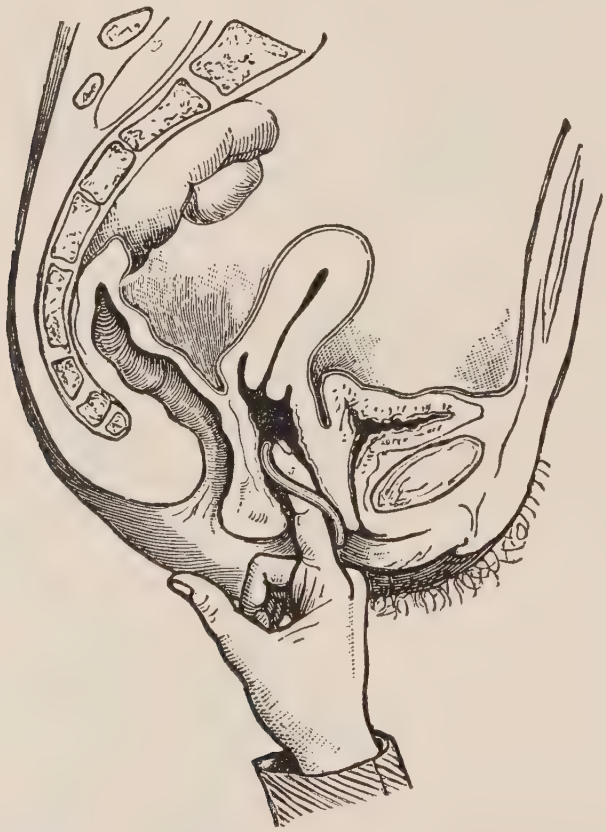

Second Stage: Pessary carried on by Finger (Hart and Barbour).

antiseptically; the pubic spine is taken as the first landmark; an incision is then made, 2 inches long, from that point upward and outward, in the direction of the inguinal canal; the incision is deepened until the tendon of the external oblique is seen; the external abdominal ring is now visible; the intercolumnar fascia is cut through in the long diameter of the ring; if necessary the incision may be continued up to the internal ring; the round ligament can

usually now be seen, with the genital branch of the genito-crural nerve along its anterior surface. The ligament is then separated from neighboring structures and gently drawn out a little to show that it is free. Alexander then leaves this side covered with a clean sponge and operates on the other side in the same way. The uterus is then thrown forward by the sound in the hands of an assistant and the ligaments drawn out till they are felt to control the uterus; the ligaments are then given to an assistant to hold, and they are each sutured with catgut to the pillars of the ring; the bruised ends are cut off and the wound closed. The patient is kept in bed two to three weeks, and wears a pessary for several months.

What are the indications for Alexander's operation?

The field of the operation is very limited. Where a retroverted uterus is movable, unaccompanied by disease of the appendages, and either cannot, with comfort to the patient, be held in position by a pessary, or the patient is unwilling to wear a pessary, Alexander's operation may be employed. Some men employ it as a part of the operative treatment of prolapsus uteri.

What are the advantages of Alexander's operation as compared with hysterorrhaphy?

In Alexander's operation the uterus itself is only held by ligaments which normally hold it. It is therefore better fitted for growth in pregnancy than where the fundus is firmly attached.

It is performed without invading the peritoneal cavity, and leaves the patient with a moderately movable uterus.

What are the objections raised to Alexander's operation?

It is not applicable unless the uterus is freely movable.

The ligaments are sometimes difficult to find; one or both may be poorly developed.

Hernia occasionally, though rarely, occurs.

The round ligaments are not true ligamentous structures, but muscular cords, and it is doubtful whether they are to be considered as normal supports of the uterus. Hence, when tension is put upon them, they are likely to stretch.

What are the synonyms of hysterorrhaphy?

Ventral suspension, ventrofixation, and hysteropexy.

Describe briefly the operation of hysterorrhaphy for retroversio-flexio.

The abdomen is opened in the median line as for an ovariotomy; the adhesions binding the uterus backward are broken up, the fundus brought forward and the uterus stitched to the anterior abdominal wall. The sutures are usually two in number, of either silk or chromicised catgut, and are inserted one just posterior to the middle of the fundus and the other posterior to that, so that when the sutures are tied the uterus will be slightly anteverted. These sutures pass through aponeurosis, muscle, and parietal peritoneum of one side, then through a portion of the fundus of the uterus, then through parietal peritoneum, muscle, and aponeurosis of the other side. These sutures are buried in the closure of the abdominal wound.

Another method is to pass the suture through the entire thickness of the abdominal wall, then through the fundus and out through the abdominal wall. This suture can be removed later and avoids the possibility of later trouble from a non-absorbable buried suture.

The usual antiseptic dressing is applied. A pessary is often inserted for a time.

What are the indications for hysterorrhaphy?

Hysterorrhaphy is indicated in a retroverted fixed uterus, especially where pregnancy is improbable; in a retroverted uterus after the removal of both appendages; as one stage in the operation for prolapsus uteri. Kelly says: "Suspension of the uterus should be resorted to only in cases of persistent retroflexion which refuse to yield to simple plans of treatment through the vagina, and then only when the discomforts of the retroflexion are sufficient to interfere seriously with health."

What are the disadvantages of hysterorrhaphy?

Experience shows that in pregnancy following hysterorrhaphy the portion of the uterine wall behind the point of suture is that which undergoes the chief distention and thinning. Although obstetric accidents due to the operation are rare, disturbances of parturition, and even rupture of the thinned posterior uterine wall, may occur.

What modification has Kelly advocated to obviate the disadvantages of hysterorrhaphy?

He sutures the fundus to the abdominal wall with two silk sutures,

both passed through the posterior aspect of the uterus behind a line connecting the inner ends of the Fallopian tubes. These only include with the fundus the parietal peritoneum and subperitoneal connective tissue. The fundus is not so firmly secured as by the former method. It gradually recedes from the abdominal wall and is connected with it by a band of adhesions. In subsequent operations on patients so treated Kelly has found this band measuring three to five centimeters.

What is the chief force in retaining the uterus in a forward position after hysterorrhaphy or Alexander's operation?

It is intra-abdominal pressure now brought to bear on the posterior aspect of the uterus.

Describe briefly intra-abdominal shortening of the round ligaments.

After opening the abdomen and separating the adhesions, the uterus is brought forward into normal position and held there by taking up the slack in the round ligaments. This is done by folding each round ligament upon itself and suturing the folds in apposition.

Prolapsus Uteri.

What is meant by the expression?

Hart and Barbour define prolapsus uteri as a downward displacement of entire displaceable portion of pelvic floor, uterus and appendages past entire fixed portion, with coincident descent of small intestine.

What is meant by the "entire displaceable portion of pelvic floor"?

"The entire displaceable portion comprises bladder, urethra and vaginal walls. It has resting upon it the uterus, broad ligament, Fallopian tubes and ovaries."

What is the "entire fixed portion of pelvic floor"?

That outside of the entire displaceable portion, *i. e.*, tissue attached to the posterior surface of the symphysis; all outside the inner aspect of the levatores ani; the rectum and tissue attached to the sacrum.

What are the degrees of prolapsus uteri?

According to Thomas there are three :—

1. When the organ has sunk in the pelvis.
2. When the cervix is at the ostium vaginæ.
3. When a part or the whole of the uterus lies between the thighs.

What is the etiology?

The three elements in the etiology of prolapse are—

1. Relaxation of the ligaments of the uterus, combined with lack of tone in the entire displaceable portion of the pelvic floor and "slackening of loose tissue around it."

2. Lack of support in the entire fixed portion of the pelvic floor, especially laceration of the perineum.

3. Intra-abdominal pressure.

The chief predisposing causes are parturition, laborious occupations, anything increasing weight of the uterus, advanced age. Prolapse is sometimes produced acutely by blows, falls, heavy lifting, etc., but is usually the gradual result of the three elements mentioned above.

What are the symptoms?

Those of the acute prolapse are sudden, severe pain, vomiting, retention of urine and signs of peritonitis. The symptoms of the gradual prolapse are a dragging sensation in lower abdomen and back, and the discomfort from the protrusion and excoriation of the parts; difficulty in urination is sometimes present.

What are the physical signs?

These depend on the degree of the prolapse. If the prolapse is partial, the anterior vaginal wall bulges at the ostium vaginæ, the cervix is lower than normal, and if there is marked laceration of the perineum the posterior vaginal wall also bulges. The uterus becomes more and more retroverted as it sinks in the pelvis. When the prolapse is complete, the cervix and more or less of the body of the uterus lies outside of the vulva; the anterior vaginal wall and part of the lower bladder wall have prolapsed with the cervix; the posterior vaginal wall with or without part of the anterior rectal wall is also everted. The uterus is usually enlarged and the supravaginal portion of the cervix elongated.

From what must you differentiate prolapsus uteri?

1. Hypertrophy of the cervix:—

(*a*) Vaginal portion; (*b*) Supra-vaginal portion; (*c*) Intermediate portion.

2. Cystocele.
3. Rectocele.
4. Inversion and polypi.

How would you differentiate prolapsus uteri from a cystocele?

In prolapse the uterus is sunken in the pelvis; in cystocele the uterus lies in nearly its normal position, and the protruding mass is found, by the introduction of the sound into the bladder, to consist of the anterior vaginal and posterior vesical wall.

How would you differentiate prolapsus uteri from a rectocele?

In prolapse the uterus is sunken in the pelvis; in rectocele, pure and simple, the uterus lies in nearly its normal position, and the protruding mass is found, by the introduction of the finger into the rectum, to consist of the posterior vaginal and anterior rectal wall.

Both cystocele and rectocele are common complications of prolapsus uteri.

What is the treatment of prolapsus uteri?

1. By pessaries; 2. By operation.

If the prolapse is slight in amount, the perineum preserved, and the anterior vaginal wall protrudes but a little, a pessary like that of Albert Smith may suffice to hold up the uterus. If this fails, a ring pessary will sometimes answer.

If the prolapse is marked, the following combination of operations or of some of them give good results:

1. Curettage of the uterus;
2. Amputation of the cervix;
3. Anterior colporrhaphy;
4. Perineorrhaphy;
5. Hysterorrhaphy.

These can all be done at the same sitting. In some cases 1, 2, or 3 may be omitted, in others the plastic operations will suffice without the hysterorrhaphy, but in a well-marked case all five are indicated.

Vaginal hysterectomy is very seldom indicated for prolapsus uteri.

Laceration of Perineum and Relaxation of Vaginal Outlet.

What is the etiology?

The most common cause of laceration of the perineum is childbirth, either natural or instrumental; rarely, however, it may arise from external violence, as falling astride of some sharp object. This occasionally happens to little children. Relaxation of the vaginal outlet, aside from being produced by these visible lacerations, is also caused by submucous and subcutaneous rupture or overstretching of the fibres of the levator ani muscle, or perineal fascia; this, too, occurs most often during parturition.

What are the varieties of perineal laceration?

1. Median. They may be:—

a. Incomplete, extending more or less deeply into the perineal body.

b. Complete, extending through the sphincter ani and up the rectum for a variable distance. Complete lacerations are less likely to be followed by relaxation and rectocele than are the incomplete.

2. Lateral. These result in a separation of some of the fibres of the levator ani on one or both sides from their attachment into the tendinous portion of the perineal body. Such tears may lie entirely within the vagina, the "skin perineum" remaining intact.

3. Perineal relaxation. Cases without apparent distinct tear, but with all their results. These are cases where there has been more or less subcutaneous rupture of levator ani fibres due to overstretching.

What is the importance of laceration of the perineum?

It consists in the fact that in cases of marked laceration, the fibres of the levatores ani, the chief support of the vaginal outlet, are torn; especially those fibres which are attached to the rectum; at the same time there is laceration of the fibres of the perineal fascia. These conditions cause relaxation of the vaginal outlet, with a tendency to rectocele, cystocele and prolapsus uteri.

If the laceration is through the sphincter ani, incontinence of fæces usually results.

What are the subjective symptoms of laceration of the perineum with relaxation of the vaginal outlet?

The patient usually feels incapacitated for any great exertion, complains of a dragging pain in the back and the feeling of weight in the pelvis.

What does a physical examination show?

An enlarged vaginal orifice, cystocele or rectocele; the anus may be drawn back toward the tip of the coccyx by the sphincter ani fibres attached to its tip and now unopposed by the torn anterior fibres of the levator ani; the depression between the buttocks at the bottom of which is the anus may be less deep than usual owing to the relaxation and descent of the pelvic floor.

How would you determine relaxation of the vaginal outlet?

Insert the thumbs or index fingers into the vaginal orifice; separate the labia by carrying the thumbs or fingers backward and outward, at the same time telling the patient to strain; the lax condition of the outlet will then be readily felt, and anterior and posterior vaginal walls will be seen to protrude.

What are the principal operative procedures for repair of lacerated perineum or relaxation of the vaginal outlet?

The four following operations are in common use—

1. Hegar's operation.
2. Emmet's operation.
3. The Saenger-Tait operation.
4. Cleveland's operation.

Describe the Hegar operation. (Martin suture.)

In this as in all perineal operations, the patient's bowels should be freely moved and the vulva shaved. Just previous to operation, the vagina and vulva should be thoroughly cleansed with soap and water and then irrigated with an antiseptic solution. In the Hegar

denudation which is triangular in shape (see Fig. 30.) three points are taken, A. B. and C. That which is to be the apex of the triangle, A, is in the median line of the posterior vaginal wall; this is seized with a bullet forceps or tenaculum and drawn upward and forward. The points B and C, at the extremities of the base line, are points on the labia majora which when the operation is completed will form the fourchette. These points B and C are also seized by bullet forceps or tenacula and are drawn apart, thus facilitating the denudation of the triangular area A. B. C.

Fig. 30.

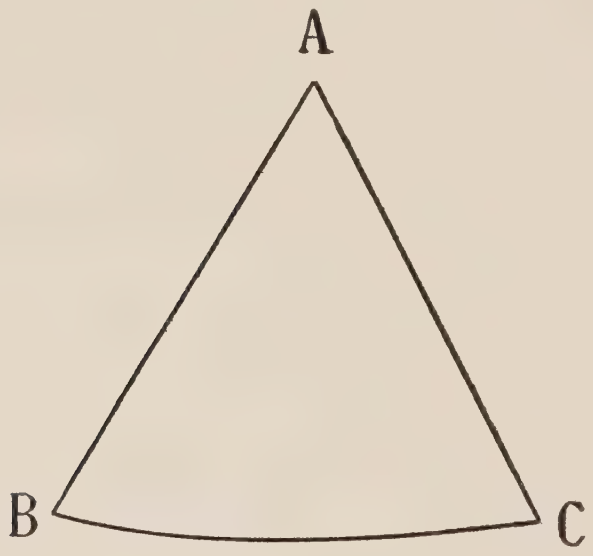

This denuded surface may either be closed by sutures introduced from side to side, or as is usually done by the author, it may be closed by a continuous catgut suture in tiers according to Martin. This is similar to the Martin method of suturing used in an anterior colporrhaphy. (See further on.)

When the operation is completed the point A is high up in the vagina, B and C are in apposition.

Hegar's operation is best suited to tears which are median or to cases where time is an important element, as in prolapse cases where the perineorrhaphy is but one of several operations performed at a sitting.

Describe Emmet's operation for restoration of the perineum.

The patient is prepared for operation as usual, with antiseptic douches, etc. She is anæsthetized and placed in the lithotomy position; a point is selected in the centre of the crest of the bulging posterior vaginal wall, and a point on each labium majus corresponding to the lowest vestige of the hymen. These three points are to be brought together by the completed operation.

Between the central point chosen and the two lateral are two triangular areas, with apices running into the vaginal sulci on each side of the columna. These triangular areas are first denuded as follows: One tenaculum is inserted into the central point chosen, and another into one of the lateral points; these are given to an assistant, who draws the central point forward and to the side opposite the other tenaculum. This draws the apex of the triangle nearly in line with the two tenacula; a narrow strip is then denuded with the scissors along this line. When the tension is relieved, the area marked off is seen to be triangular, as before. The denudation of this triangle is then completed by long snips of the scissors. The lateral point on the other side is now seized with the tenaculum, and the central point drawn toward the denuded side; this triangle is denuded as before, also, as much of the skin surface of the perineum as is necessary. The parts are now thoroughly irrigated and the sutures introduced as follows: The two triangular areas are to be in the vagina, and are sutured with either silkworm gut or catgut. The apex of one triangle is first closed, the suture entering and emerging from the vaginal mucous membrane near the denuded surface; the succeeding sutures of this triangle are made to enter the vaginal mucous membrane on one side, slant toward the operator, emerge at the centre of the denuded surface, re-enter, slant away from the operator and emerge from the mucous membrane of the other side a little in front of the preceding suture. This method is repeated in the other triangle. There then remains but a small external denuded area to be closed; this is best done with silkworm gut. The upper or crown suture, entering the skin on one side, passes through the anterior extremity of the columna of the posterior vaginal wall, and emerges from the skin on the other side. The bowels are moved about the third day and the sutures removed on the eighth. This is an excellent operation for bilateral tears. The two triangles denuded

up into the vagina lie in two depressions formed by the separation of levator ani fibres from their attachment. Hence when the sides of these triangles are brought together the tendency is to bring the levator ani fibres into apposition with the perineal body. Students find difficulty in understanding this operation from written descriptions, but will find it quite simple when once they have seen the triangles located on the living subject.

Fig. 31.

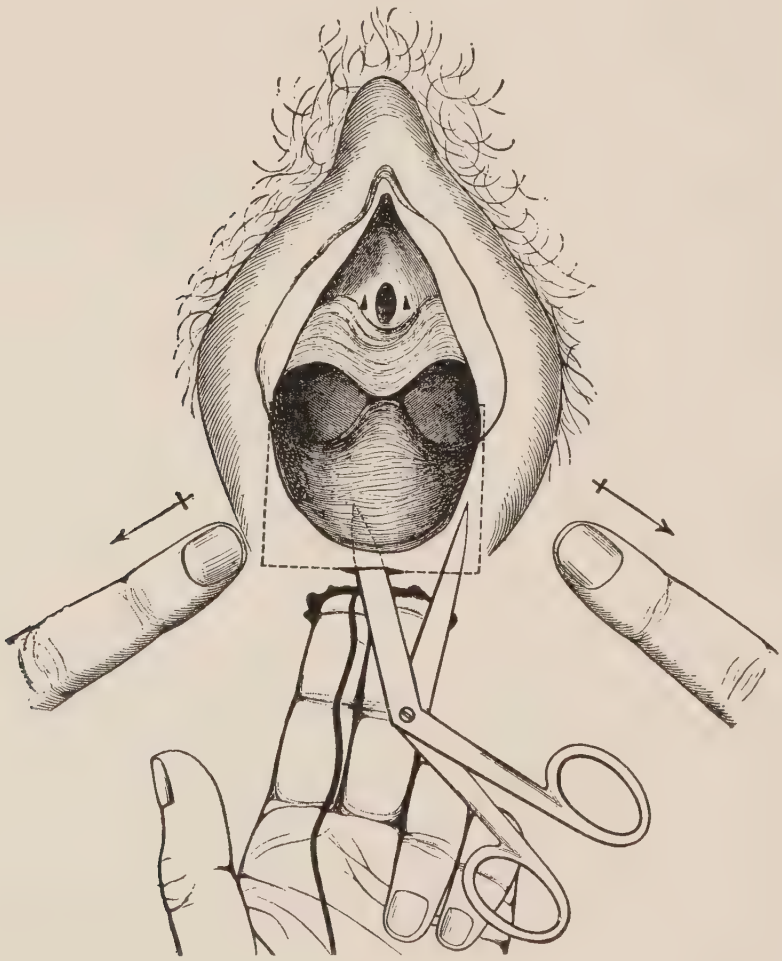

Describe the Saenger-Tait operation.

The patient is prepared for operation by having the bowels freely moved, the vulva shaved, and an antiseptic vaginal douche given. She is then anæsthetized and placed in the lithotomy position, with

knees supported by Clover's crutch and hips resting on Kelly's perineal pad. The vagina and vulva are now scrubbed with soap-water and irrigated with an antiseptic solution, and an assistant so stationed that he can allow a mild antiseptic solution or sterilized salt solution to trickle on the wound during the operation. A tampon is inserted into the rectum, the string left projecting. The index and middle fingers of the left hand are now inserted into the rectum, as seen in Fig. 31; the labia are separated by an assistant, the blades of the scissors (Tait uses angular scissors and inserts only one blade; scissors curved slightly on the flat, with points rather sharp, and both blades inserted, may be used with advantage) inserted into the recto-vaginal septum just in front of the anus, and the vaginal and rectal mucous membranes separated for some distance around the point of insertion. A horizontal incision is now made through the point of insertion, extending on either side to a perpendicular through the lower extremity of the nymphæ; an incision is made with the scissors up along this perpendicular to the lower extremity of the nymphæ. The flap so marked out is then dissected up to the crest of the bulging posterior vaginal wall. See Fig. 32.

The parts are now freshly irrigated, and the sutures of silver wire introduced as follows: Either a Peaslee's needle or a long, straight needle with a thread loop may be used; the sutures, 3–4 in number, are inserted just within the denuded area on one side, and brought out just within the denuded area on the other. See Fig. 33. The tampon is removed from the rectum, the sutures twisted up and either left long or shotted and cut short. The skin is now brought into apposition by superficial silkworm-gut sutures introduced between the wires, giving the result seen in Fig. 34. An antiseptic dressing and a T-bandage are applied, and the patient is put to bed.

The bowels are moved about the third day, and the sutures removed on the eighth. This operation has no advantages over the Emmet perineorrhaphy.

What is a good method of procedure when the laceration extends through the sphincter ani?

Thoroughly cleanse the vagina and lower portion of the rectum. Denude a V-shaped area with apex up the rectum, representing the torn wall of the latter, and with the arms of the V resting on the ends of the divided sphincter ani muscle. The denuded sur-

FIG. 32.

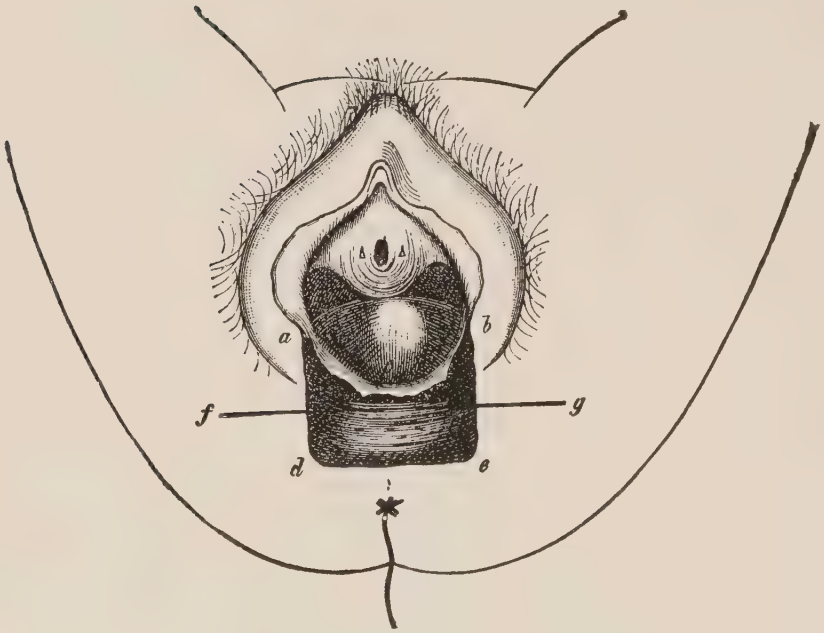

FIG. 33.

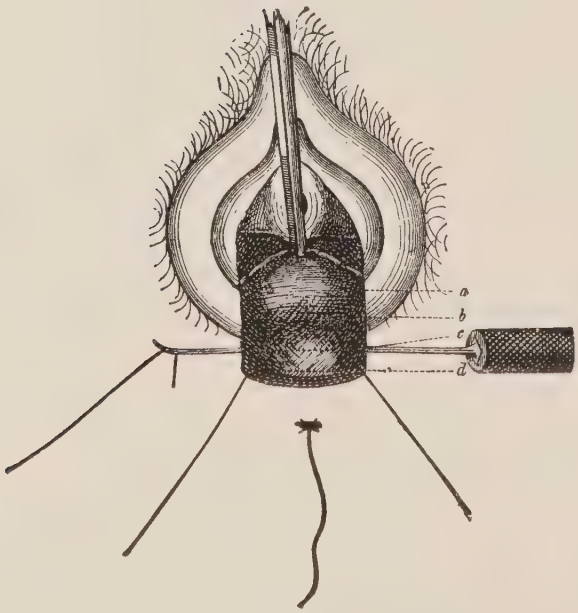

face had best be a little larger at these latter points. It is well to dissect out and identify the torn ends of the sphincter to insure their being brought together by the sutures. Sutures of silkworm gut or chromicized gut are now introduced as seen in Fig. 35 with ends in the rectum and tied. The ends of the silkworm gut sutures are left long and protruding from the anus. This repairs the rectal rent, and now the further restoration of the perineum may be accomplished by any of the ordinary methods of denudation and suturing. The Hegar's denudation with Martin's suture answers admirably here.

Fig. 34.

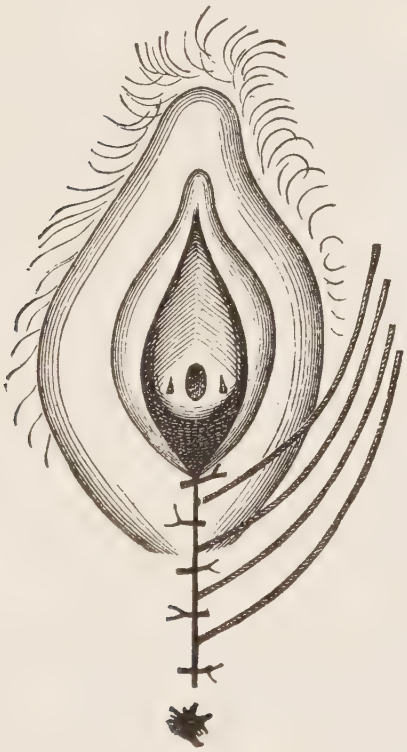

Fig. 35

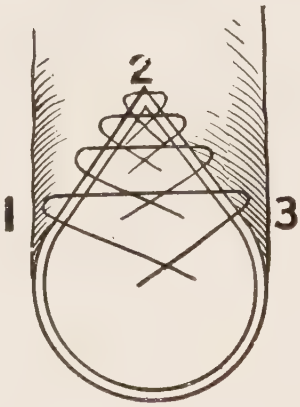

Describe the Cleveland operation.

Dr. Cleveland describes his method in the following words—"The usual broad denudation, extending well into the sulci having been made, the first suture is passed in at the centre (see Fig. 39. *A*, 1.) of the denuded surface on the patient's left, a quarter of an

inch from the edge, is carried well back, deep under the tissues, to embrace the retracted muscles, across between the denuded surface and the rectum, to the centre of the denuded surface, then down

Fig. 36.

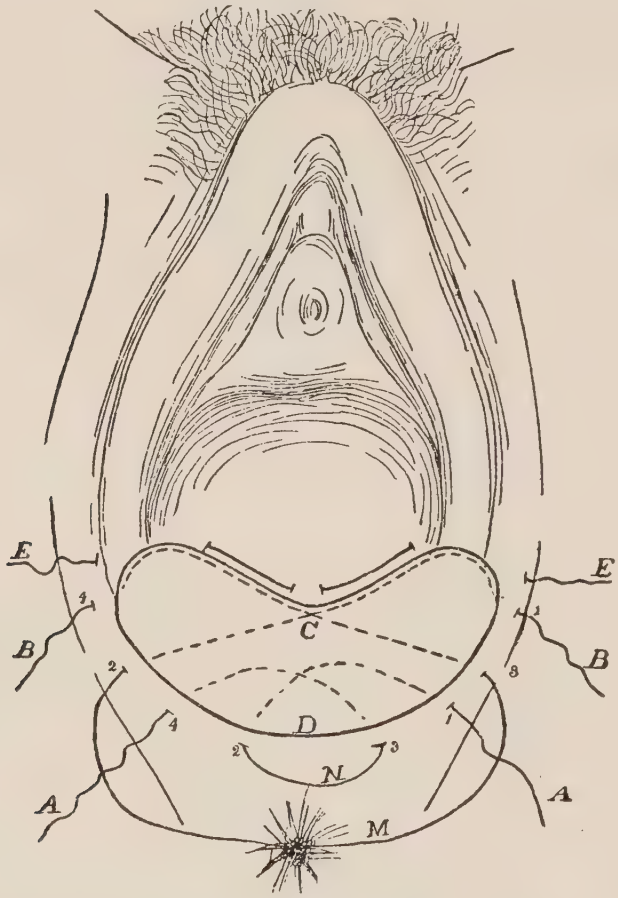

and out a quarter of an inch from the edge, at a point (2, Fig. 36.) midway between the centre of the denuded surface on the patient's right, and the posterior commissure *D*. It is then carried over without cutting, and entered at a corresponding point (3, Fig. 36.) opposite the point where it was brought out; then carried up, buried, to the centre of the denuded surface, across, and out a quarter of an inch beyond the centre of denuded edge (4, *A*, Fig. 36.), directly opposite the point where it was first introduced. The second suture, or suture *B* in the diagram, is introduced just below the summit of the denudation on left labium (1, *B*. Fig. 36.), and

passed, buried close to the denuded edge, around the angle in the left sulcus to the highest point of denuded surface on the columna, at *C*, then across, still buried, the angle of right sulcus and out at 2. *B*, which is a point midway between summit and centre of denudation on right labium: then carried over without cutting and is entered at 3. *B*, a point corresponding to the one where it was just brought out, then across, buried, the angle of left sulcus to the point *C*, and finally passed around the angle of right sulcus close to the denuded edge and out at 4. *B*. a point corresponding to 1. *B*."

Dr. Cleveland often introduces a third suture *E*. as a protection suture. They are usually of silk-worm gut. The sutures are now drawn up and tied beginning with *A*.

Describe the operation of anterior colporrhaphy.

This consists in the denudation of an elliptical piece of mucous membrane from the anterior wall of the vagina, and suturing together the raw area thus formed. The ellipse should extend from a little behind the urethral prominence to a point just in front of the cervix. The denudation is usually best performed with scissors, removing the mucous membrane in long strips. The strip to be removed is held taut with toothed thumb-forceps drawn toward the operator, and the ridge thus formed is removed by scissors cutting in the opposite direction and held parallel to the surface of the ridge. The suturing is best done, according to Martin's method, by a continuous suture of catgut, as follows: A line of suture is first made longitudinally along the centre of the denuded ellipse; this reduces its size slightly; another tier of sutures is then inserted back over the first, uniting tissue more superficial; thus the sutures are introduced tier upon tier, each narrowing the denuded area and causing the edges of the mucous membrane to approach each other, till finally in the last tier these edges are included.

In Stoltz's method the denudation is as described above, but the suturing is done by means of a single purse-string suture which surrounds the denudation and, when drawn tight, puckers it together.

This operation may be combined with any operation on the perineum and posterior vaginal wall.

Hypertrophy of the Cervix.

Give the varieties and etiology.

Hypertrophy of the cervix may involve either the infra-vaginal or supra-vaginal portions. Some authorities mention hypertrophy of the intermediate portion of the cervix.

Little is known of the etiology.

Hypertrophy of the infra-vaginal portion is usually congenital.

Hypertrophy of the supra-vaginal portion usually accompanies prolapse of the uterus or vaginal walls.

What are the physical signs and symptoms?

The os is nearer vulva than normal; it may even project beyond the vulvar opening.

In hypertrophy of the infra-vaginal portion, the cervix is long, usually conical, with small os; the vaginal fornices and fundus uteri are in their normal position. If the cervix protrudes from the vulva, it may be ulcerated, from friction.

"In hypertrophy of the supra-vaginal portion both anterior and posterior fornices are obliterated."

"In hypertrophy of the intermediate portion the posterior fornix remains, while the anterior fornix is obliterated." (Hart and Barbour.)

What are the symptoms?

The symptoms of hypertrophy of the infra-vaginal portion are chiefly mechanical:—

Leucorrhœa, from vaginal irritation.
Discomfort in exercise.
Sense of weight in the pelvis.
Sterility.

The symptoms of hypertrophy of the supra-vaginal portion are those of the prolapse of the uterus or vaginal walls, which it usually accompanies.

What is the treatment of hypertrophy of the infra-vaginal portion of the cervix?

Amputation of the cervix.

The best method is probably a circular amputation, proceeding in a manner somewhat similar to that employed in amputation of an extremity, viz, cutting through and retracting superficial struc-

tures, go through cervix higher up, thus making the portion of cervix removed conical. The tissues retract so that the stump left also appears conical, but the superficial structures can easily be brought over it. The vaginal mucous membrane opposite the uterine canal is stitched to the mucous membrane of the cervical canal both anteriorly and posteriorly, care being taken to make the sutures include a portion of the substance of the cervix so as to fasten the flaps down to the stump to prevent oozing and pocketing. At the sides of the cervix the flaps will usually come into easy apposition and should be sutured together, taking care as above, that the sutures include the deeper structures and prevent oozing. The lines of suture thus extend from the os a little way into each lateral fornix. Before the cervix is completely removed a few of the sutures may be introduced and used as tractors.

Another very good method is that of Simon and Marckwald, in which the cervix is first divided by a transverse incision into an anterior and posterior lip; a wedge-shaped piece is then removed from

Fig. 37.

Marckwald's method of splitting the cervix into an anterior and posterior lip and then uniting cervical to vaginal mucous membrane (*Schroeder*).

each (see Fig. 37), and the flaps of each lip are brought together with sutures, either of silk worm gut, catgut, or silver wire.

Stenosis of the Cervix.

What is the etiology?

It may be either congenital or acquired. When congenital, it is usually associated with a small uterus, long cervix, and anteflexion. Stenosis of the external os is more frequent than of the whole canal.

Acquired stenosis results from cicatrization following the use of too strong caustics, endocervicitis, or a too complete closure of the cervical canal in a trachelorrhaphy.

What are the symptoms?

Dysmenorrhœa and sterility The stenosis results in an insufficient drainage of the cervical canal. The retained secretion gives rise to an endocervicitis which, rather than the stenosis, is to be considered the direct cause of the sterility.

What is the treatment?

Dilate the cervix with one of the glove-stretcher dilators and maintain the dilatation by the occasional introduction of graduated sounds. Iodoform gauze packing may be used for the first few days following the dilatation of the canal.

Laceration of the Cervix.

What is the etiology?

The usual cause is parturition or abortion; it occasionally occurs as a result of mechanical dilatation of the cervix. It occurs in parturition in about 32 per cent. of women; especially in tedious, precipitate or instrumental deliveries. It is predisposed to by a rigid os, faulty presentation or condition of the fœtus, premature rupture of the membranes and previous disease of the cervix.

What is the pathology?

The laceration may be—

1. Complete. Penetrating the whole thickness of the cervix.
2. Partial. Including cervical mucous membrane, but not appearing on the vaginal surface.

It may be—

(*a*) Unilateral (see Fig. 38).
(*b*) Bilateral.
(*c*) Stellate (see Fig. 39).

The unilateral laceration is most apt to occur in the line of the

right oblique diameter of the pelvis, *i. e.*, either anteriorly and to the left or posteriorly and to the right, especially the former. This

FIG. 38.

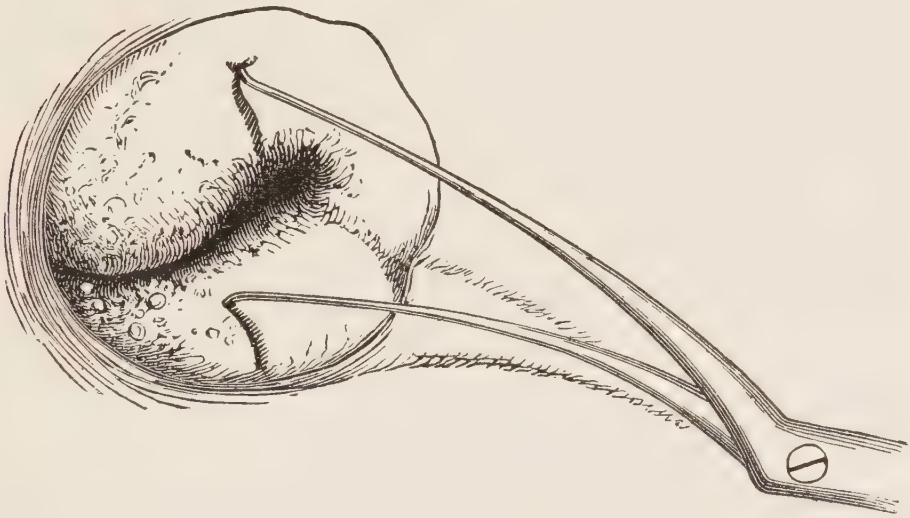

Single Laceration. The flaps are held apart with a double tenaculum (*Emmet*).

FIG. 39.

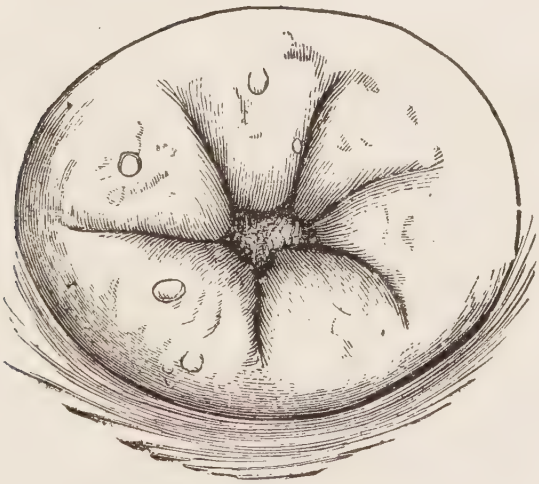

Multiple or Stellate Laceration (*Emmet*).

is supposed to arise from the greater frequency of the first position of the vertex.

Bilateral lacerations are usually more dangerous than those of the anterior or posterior lip, because opening up the cellular tissue of the broad ligaments.

Stellate lacerations are more apt to be superficial.

If the surfaces of laceration are kept clean, more or less union will occur. Usually there is partial union, with eversion and proliferation of the cervical mucous membrane, hyperplasia of the connective tissue and proliferation of the glandular structure.

What are the complications and results?

The most frequent complications are—

1. Cellulitis.
2. Peritonitis.
3. Endometritis, especially cervical endometritis.

The common results are—

1. Subinvolution.
2. Chronic metritis.
3. Displacements of the uterus.
4. Sterility.
5. Abortion.
6. Epithelioma.

If the laceration has extended through the anterior fornix, a vesico-vaginal or vesico-uterine fistula may remain.

What are the symptoms?

The symptoms are due to the inflammatory processes to which the laceration gives rise.

The patient usually complains of a feeling of weight in the pelvis; leucorrhœa, disturbances of menstruation, especially menorrhagia; sterility; neuralgia and various reflex neuroses, such as suboccipital headache. At the time of the laceration there may be considerable hemorrhage.

What are the physical signs?

On making a vaginal examination the cervix usually feels enlarged and more sensitive than usual; the fissure can, as a rule, be readily detected; also, if present, the eversion of the cervical mucous membrane, which usually feels velvety, often granular or cystic. Sometimes the eversion is so extreme that one does not notice the fissure, simply feeling the velvety or granular area about the os. The latter may be so patulous as to admit the finger. On making the bimanual examination the uterus is often found enlarged as a

whole; cicatrices may be felt extending from the laceration into one of the vaginal fornices. With the aid of the speculum one sees the erosion on one side of or surrounding the os, and by drawing the edges of the laceration together with tenacula the extent of the tear is visible. Without this latter procedure, one is greatly deceived, in some cases, as to the degree of the injury.

What is the treatment?

Opinions differ as to whether lacerations of the cervix, unless accompanied by hemorrhage, should be immediately repaired or not. When hemorrhage accompanies the laceration, the cervix should be drawn down to the vulva and the laceration closed with silkworm gut or catgut sutures.

The treatment after the puerperium is as follows: The complications, if present, are first treated, especially peritonitis or cellulitis, by counter-irritation, hot-water vaginal douches, glycerine tampons, etc.

The cervical endometritis is treated by pricking the cysts, if present, and applying to the cervical mucous membrane carbolic acid, iodized phenol, or alumnol, 10 per cent. in glycerine. The corporeal endometritis is treated by the curette, if necessary, and applications as in cervical endometritis.

The growth of the squamous epithelium over the erosions is stimulated by astringent applications, especially pyroligneous acid. Under the above procedures the uterus often returns to its normal size, and the symptoms associated with the laceration disappear.

If the symptoms continue after the foregoing treatment, and neither peritonitis nor cellulitis is present, Emmet's operation of trachelorrhaphy is indicated.

Describe briefly the operation of trachelorrhaphy.

The patient, after the usual preparation regarding bowels, bladder, and antiseptic vaginal douche, is anæsthetized and placed in the dorsal position, with Kelly's pad beneath the hips, and legs supported with a leg-holder. The vulva and vagina are thoroughly scrubbed with soap and water, and an antiseptic douche given. The perineum is retracted with a speculum; the anterior lip of the cervix is seized with a bullet-forceps, and the uterus drawn down and steadied by an assistant.

The edges of the laceration are now pared with scissors or knife,

giving the denuded area seen in Fig. 40, and leaving enough mucous membrane in the centre for the cervical canal. Care should be taken to excise the plug of cicatricial tissue at the angle of the laceration. The parts are now irrigated with an antiseptic solution, and the sutures of silkworm gut or silver wire introduced, usually 3–4 on a side, beginning at the upper angle. Each is passed from the surface of the vaginal portion, through the thickness of one lip, emerging in the edge of the undenuded mucous membrane; thence is passed into the edge of the undenuded mucous membrane of the other lip, through the lip's substance, and emerges on the surface of the vaginal portion. The other sutures of the same side are introduced in a similar man-

Fig. 40.

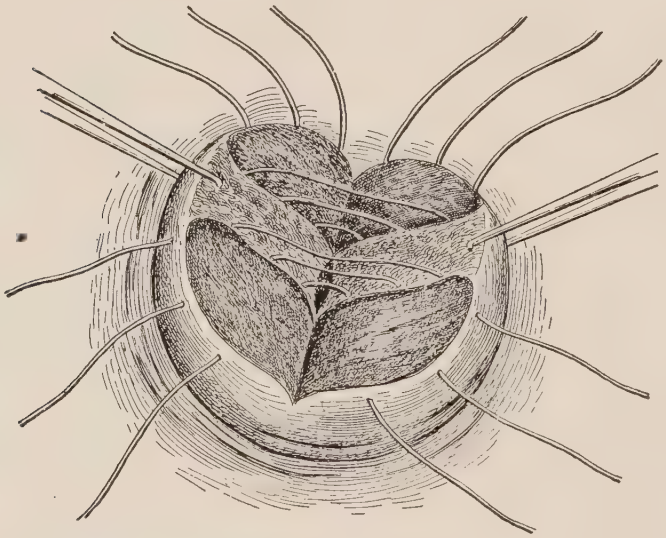

Trachelorrhaphy for Bilateral Laceration of the Cervix Uteri. Sutures introduced.

ner, care being taken to bring the parts into close apposition and leave no pockets. If the laceration is bilateral, the suturing of the other side is conducted in the same manner. The parts are again irrigated, and the sutures tied or twisted up. A sterile dressing is applied to the vulva and the patient placed in bed. The sutures are left 8–10 days; they may be left longer if the peritoneum is repaired at the time of the trachelorrhaphy.

Endometritis.

Define and give the varieties.

Endometritis is an inflammation of the lining membrane of the uterus; it may be either acute or chronic. Acute endometritis usually involves both cervix and body.

The chronic is often confined to either cervix or body, and called in the former case cervical endometritis, endocervicitis, or chronic cervical catarrh; in the latter case, corporeal endometritis.

Occasionally, chronic endometritis affects the whole uterus.

Acute Endometritis.

What is the etiology?

Before puberty it is rare. The most common causes are the following:—

1. Traumatism and sepsis, especially from dirty instruments.
2. Gonorrhœa.
3. Catching cold during menstruation.
4. Excessive coitus near menstruation.
5. Severe types of the exanthemata.
6. It is one of the lesions in puerperal septicæmia.

What is its bacteriology?

It is most often due to the gonococcus, less often to the pyogenic streptococci and staphylococci.

What is the pathology?

Usually the endometrium of both body and cervix is involved, but the former more than the latter. The mucous membrane is swollen and softened; extravasations of blood into it occur; the epithelium is in places destroyed and desquamated. The secretion is first serous, later purulent, perhaps bloody.

What are the complications?

The most common are—

Vaginitis; Urethritis; Salpingitis; Peritonitis.

What are the physical signs?

The cervix is enlarged, soft and slightly sensitive; the endometrium is very sensitive to the sound or probe, and these should be avoided. There is often an erosion about the os, which is usually filled with a ropy secretion. The cervix sometimes looks and feels like that of early pregnancy.

What are the symptoms?

The characteristic symptom is the discharge, which is first watery, then creamy. In mild cases there are usually no constitutional symptoms save a feeling of weight in the pelvis and a slight malaise. In more severe cases there is a dull pain in the back and pelvic region, irritability of the bladder, and a slight rise of temperature.

What is the treatment?

Put the patient to bed; give light diet; move the bowels freely with a saline cathartic; administer large hot vaginal douches (water Oviij, borax ʒviij), temperature 110°–115°, three or four times a day for the first 24–48 hours. Later insert glycerine tampons and continue douches less frequently. Depletion by scarification of the cervix is often of value. Hot applications to the abdomen usually suffice for the relief of pain.

Chronic Endometritis.

What are the varieties?

(*a*) Chronic cervical endometritis.
(*b*) Chronic corporeal endometritis.

A. Chronic Cervical Endometritis.

What are the synonyms?

Chronic cervical catarrh and endocervicitis.

What is the etiology?

Chronic cervical endometritis is predisposed to by any low state of the system, from whatever cause produced.

The most common exciting causes are—

(*a*) Laceration of the cervix.
(*b*) Extension upward of a vaginitis.
(*c*) Extension downward of a corporeal endometritis.
(*d*) Displacements of the uterus, especially flexions.
(*e*) Stenosis of the cervix.
(*f*) Traumatism, especially septic.
(*g*) Excessive coitus.
(*h*) Catching cold during menstruation.

What is the pathology?

In mild cases the mucous membrane alone may be involved, but

often more or less of the substance of the cervix is affected. In a well-marked case the epithelium, glands, and interstitial tissue are all involved in the change.

The cylindrical epithelium of the canal proliferates and replaces the squamous epithelium on the vaginal portion of the cervix. This is especially true where the cervix is lacerated, and the cervical mucous membrane is everted.

The glands of the cervix are hypertrophied and proliferated, and in addition to this, according to Ruge and Veit, the surface of the mucous membrane is thrown into numerous folds, producing glandular recesses and processes, which may later form cysts.

The connective tissue of the cervix is also increased.

The reddened areas about the os, where cylindrical epithelium has replaced the squamous, and the glandular structure has increased, are called erosions, sometimes wrongly spoken of as "ulcerations."

What are the so-called cervical erosions?

The term has been applied to a number of distinct pathological conditions:

1. Small ulcers without epithelial covering.
2. A congenital ectropion of the uterine mucosa.
3. Pseudo-erosions. They are covered by a single layer of cylindrical epithelium and are due to two distinct processes: First, there may be an outgrowth of the mucosa of the cervical canal over the exposed portion of the cervix, gradually pressing back the squamous epithelium from the external os. These heal by a reversed process, *i. e.*, a proliferation of the squamous epithelium, causing a receding of the cylindrical.

Second, the irritation of secretions may cause a maceration and desquamation of the superficial squamous cells of the cervix, leaving exposed the deeper cylindrical ones. Such erosions appear as red spots scattered over the cervix. They heal by a metaplasia of their epithelium.

What are the physical signs of chronic cervical endometritis?

In nulliparæ the cervix may feel normal, save a little swollen and sensitive; sometimes the neighborhood of the os has a granular or velvety feel.

In multiparæ, especially where the cervix is lacerated, the granular area about the os is larger, and small cysts in greater or less numbers can usually be felt.

What are the symptoms?

The characteristic symptom is the leucorrhœa; this may irritate the vulva, causing pruritus.

Pain in the back and loins, especially on exertion, is usually present, but may be slight.

Other symptoms are disturbances of menstruation, especially menorrhagia, sterility and reflex neuroses.

What is the treatment?

Attend to the general health and remove, as far as possible, the causes of the endometritis.

In mild cases, especially in nulliparæ, use hot-water vaginal douches containing an astringent, as sulphate of zinc ʒj–Oj.

If more severe, remove the ropy mucus from the canal with a large-mouthed syringe and apply iodized phenol.

When the cervix is cystic or much congested, prick the cysts or scarify the cervix.

Fig. 41.

Fig. 42.

Schroeder's excision of the cervical mucous membrane in cervical catarrh.

Fig. 41. Line of incision in mucous membrane.

Fig. 42. Mucous membrane excised and flap *bc* turned in on *ab* (*Schroeder*).

If the above treatment fails, dilate the cervix, curette thoroughly and drain the uterus with iodoform gauze.

Schroeder's operation consists in dividing the cervix into an ante-

rior and posterior lip, excising the mucous membrane by a V-shaped incision (see Fig. 41), and turning in and uniting the lips as seen in Fig. 42.

When the cervix is badly lacerated trachelorrhaphy is indicated.

B. Chronic Corporeal Endometritis.

What is the etiology?

It sometimes follows the acute, more often begins as chronic.

The most common causes are—

1. Parturition, especially when the secundines are not thoroughly removed.
2. Displacements.
3. Traumatism, especially septic.
4. Tumors, especially fibroids and polypi.
5. Excessive coitus.
6. Extension of inflammation from the cervix.
7. Chronic metritis.

What is its bacteriology?

The majority of cases are not bacterial in origin. An examination of the endometrium and secretion shows no bacteria except gonococci occasionally.

What is the pathology?

The term chronic endometritis as here used is a clinical one and covers two distinct processes:

1. A chronic interstitial inflammation having the features of a chronic inflammation elsewhere, *i.e.*, a proliferation of the connective-tissue stroma cells. Glandular changes are secondary. They may be dilated, compressed or diminished in number, due to the pressure of the new connective tissue.

2. Hyperplasia of the endometrium. This is not a true inflammation, nor due to bacteria, but the result of congestion and chemical irritation. The hyperplasia primarily affects the glands. They may be increased in length and tortuous, penetrating the mucosa in corkscrew fashion. They are frequently dilated and may form cysts. Many new ones may be formed.

If all portions of the endometrium are equally involved, then it is uniformly thickened and smooth. Often this is not the case, and

the unequal involvement of different portions of endometrium results in the formation of "uterine fungosities" and "villous endometritis."

In some cases stroma and glands are both affected.

Chronic corporeal and chronic cervical endometritis are often associated.

What are the symptoms of chronic corporeal endometritis?

(*a*) Leucorrhœa.
(*b*) Menstrual disturbances, especially menorrhagia.
(*c*) Dysmenorrhœa.
(*d*) Pain in back and pelvic region.
(*e*) Sterility.
(*f*) Abortion.
(*g*) Reflex neuroses.

What are the physical signs?

On bimanual examination the uterus is usually found more or less enlarged; perhaps a little tender.

The sound, on introduction, shows the cavity enlarged, and usually detects irregularities in its mucous membrane; it frequently causes slight bleeding.

What are common complications?

Metritis.
Salpingitis.
Peritonitis.
Displacements.
Vaginitis.

What is the treatment?

1. *Prophylactic.*—Be careful that the uterus is thoroughly emptied after labor or abortion. Avoid exposure during menstruation. Observe strict cleanliness and antisepsis in the use of uterine instruments.

2. *When no Irregularities of the Endometrium are Detected.*—Make occasional applications of iodized phenol to the endometrium. Administer internally, three or four times a day, fifteen drops each of the fluid extracts of ergot and hydrastis canadensis.

3. *When Irregularities of the Endometrium are Detected.*—If no

acute inflammation is present in the neighborhood, dilate the cervix and curette the uterus under antiseptic precautions; wash out the uterus with an antiseptic solution, making use of a double-current catheter. The curetting, if thorough, is best done under anæsthesia. It is well to confine the patient to bed for a week, and occasional applications of iodized phenol to the endometrium may be necessary. Drainage of the uterus with iodoform gauze for twenty-four hours after the curetting is often of value.

Metritis.

Describe and give the varieties.

Metritis is an inflammation of the parenchyma of the uterus, as distinguished from that of its mucous lining or serous covering. The two varieties are the acute and chronic.

Acute Metritis.

What is the etiology?

Acute metritis rarely if ever exists as an independent condition; it is almost always associated with an endometritis or peritonitis; especially the former.

The chief causes are—

1. Septic infection during or soon after labor, abortion, or operation; 2. Gonorrhœa.

Acute metritis occasionally arises from exposure to cold during menstruation or sexual excess, but these usually first produce endometritis, secondarily metritis.

What is the pathology?

The uterus is enlarged, especially antero-posteriorly, infiltrated with serum, soft and tender. The endometrium is also thickened and congested. The peritoneal investment is often covered with lymph. "Microscopically the muscular bundles are infiltrated with pus corpuscles" (Hart and Barbour). Circumscribed abscesses occasionally, though rarely, occur in the uterine walls. These often prove fatal, but sometimes are absorbed, sometimes become encapsulated and cheesy, and sometimes empty into the uterus, bladder, rectum, vagina, intestines, peritoneum, or through the abdominal walls.

Acute metritis may resolve at the end of a week; it may pass into the chronic form; if a result of puerperal infection, it is often fatal.

What are the symptoms?

They usually resemble those of acute endometritis, but are more severe. The disease is often ushered in with a rigor; temperature and pulse rise; there is pain in the hypogastrium and in pelvis. The uterus is very tender on pressure; there is nausea, usually vesical and rectal tenesmus, and menstruation, as a rule, is disturbed, sometimes suppressed; more often menorrhagia is present.

What is the treatment?

If due to sepsis, try to remove the cause; giving, if necessary, intra-uterine irrigations of bichloride (1–5000). Keep the patient quiet in bed; apply poultices or turpentine stupes to the hypogastrium; if temperature is very high, use the ice coil. Empty the bowels with saline cathartics; if pain is very severe, allow opium by suppository. Later, employ long hot-water douches and glycerine tampons. When intramural abscesses form, hysterectomy may be necessary.

Chronic Metritis.

What are common synonyms?

Areolar hyperplasia (Thomas). Chronic parenchymatous inflammation of the womb (Scanzoni). Diffuse interstitial metritis (Noeggerath).

What is the etiology?

According to Hart and Barbour, the causes may be divided as follows:—

(*a*) Causes which operate through interference with the normal involution of the puerperal uterus.

(*b*) Causes which operate through the production of repeated or protracted congestion of the uterus.

(*A*) Frequent causes of subinvolution are—

1. Retained secundines.
2. Laceration of the cervix.
3. Pelvic inflammation following parturition.
4. Rising too soon after parturition.
5. Non-lactation.
6. Repeated miscarriages.

(*B*) Causing repeated or protracted congestion are the following—

1. Chronic endometritis.
2. Displacement of the uterus.
3. Tumors near the uterus.
4. Chronic pulmonary, cardiac, hepatic or nephritic disease.
5. Excessive coitus.

Chronic metritis sometimes follows the acute but usually begins as chronic.

What is the pathology?

The pathological changes may be divided into three stages—

1. Hyperæmic; 2. Hyperplastic; 3. Sclerotic.

In the first or hyperæmic stage the uterus is enlarged, soft, tender, and contains more blood than normal.

In the second or hyperplastic stage there is an increase of the intermuscular connective tissue, with or without a slight increase of the muscular tissue. The vascularity is decreased by the growth of connective tissue around and compressing the blood vessels.

The third, or sclerotic stage is a result of the former, the uterus becoming more dense, less and less vascular and finally atrophied.

What are the symptoms?

Most of the symptoms are either due to the increased size of the uterus or to the complicating endometritis. The symptoms usually date from parturition or abortion. The following are common—

A feeling of weight in the pelvis.

Pains radiating to the back, limbs and different parts of the body.

Irritability of bladder and rectum.

Leucorrhœa.

Menstrual disturbances, especially menorrhagia, due to the endometritis.

Abortion in the early stages.

Sterility, later.

Reflex neuroses.

What are the physical signs?

The uterus in the early stages is uniformly enlarged, soft and tender; later harder, and in the late stages irregularities of shape

may be detected. The canal is enlarged in all its dimensions and the sound passes easily. The os is usually patulous; the cervix may be large and nodular.

What are common complications of chronic metritis?

(*a*) Chronic endometritis.
(*b*) Salpingitis.
(*c*) Peritonitis.
(*d*) Ovaritis.
(*e*) Vaginitis.
(*f*) Displacements.

What is the treatment of chronic metritis?

1. Prophylactic.—Care during and after confinement.
2. Curative.—

First treat the complications, if present, especially endometritis and displacements, in the usual manner. Attend to the general health, bowels, exercise, etc. Let the patient rest a part of each day, especially at menstruation; limit coitus. Weir Mitchell's treatment of rest, over-feeding and massage is sometimes of value.

Local treatment.—Prolonged hot-water vaginal douches; glycerine or boroglyceride tampons; tincture of iodine to cervix and fornices of the vagina; scarification of the cervix with Buttle's spear.

Emmet's operation of trachelorrhaphy, or amputation of the cervix by the Simon and Marckwald method is sometimes indicated.

Atrophy of the Uterus.

What is the etiology?

It is the natural condition after the menopause, and is produced artificially by the removal of ovaries and tubes. It is sometimes associated with phthisis and other exhausting diseases. It occurs as a superinvolution after childbirth, especially as a result of metritis, peritonitis, ovaritis or salpingitis. This superinvolution is the variety of most importance.

What are the symptoms?

Amenorrhœa.
Sterility.
Reflex neuroses.

What are the physical signs?

The uterus is small, both in body and cervix, and the canal is shortened.

What is the treatment?

Attend to the general health.

Before the menopause, galvanism of the uterus and ovaries may be tried.

The treatment is generally unsatisfactory.

Fibroid Tumors of the Uterus.

What are common synonyms?

Fibro-myomata and myomata. Strictly speaking, fibro-myomata is the more correct designation, as the tumors are composed of both fibrous and muscular tissue.

What is the etiology?

Little is known of the cause of fibroids. They are much more common in the African than in the white race; are most frequently found between the ages 30–45, and are said to be more common in married than in unmarried women. They rarely, if ever, begin before puberty, and never after the menopause.

What is their structure?

Fibroids, or fibro-myomata of the uterus, are tumors composed of both fibrous and muscular tissue, either of which may predominate over the other. The fibrous tissue is usually in excess.

Those composed chiefly of fibrous tissue are usually more or less encapsulated and of slow growth.

Those composed chiefly of muscular tissue are rare, not encapsulated, and are of rapid growth.

They derive their blood-supply from a network of vessels in their capsules, the central portions being without large vessels.

What are their situations?

They are much more frequent in the body of the uterus than in the cervix. They are most often found on the posterior wall, next in frequency on the anterior wall, rarely on the lateral walls. The soft, rapidly-growing fibroids are more frequent in the fundus.

The tumors always begin in the substance of the uterine walls;

they may continue their growth there; may extend into the uterine cavity, lifting up the mucous membrane, or outward, lifting up the peritoneum. Hence the three varieties:—

1. Interstitial.
2. Submucous.
3. Subperitoneal.

FIG. 43.

IM. Interstitial fibroids.
SM. Submucous. (*Schroeder.*)

Describe the three varieties.

The interstitial or intramural fibroids (see Fig. 43) are usually multiple and are situated in the substance of the uterine wall. The submucous fibroid (see Fig. 44) may be either sessile or attached by a long pedicle. In the latter case it is called a fibrous polypus.

The subperitoneal or subserous fibroids (see Figs. 45 and 46) are often multiple; may be sessile or pedunculated; may grow upward into the abdominal cavity and draw uterus up, or grow downward into the pelvis, and perhaps become incarcerated. They may form adhesions with other organs, get their nutrition through the adhesions, and become detached from the uterus. These are the most fibrous, least vascular, and slowest-growing fibromyomata.

FIG. 44.

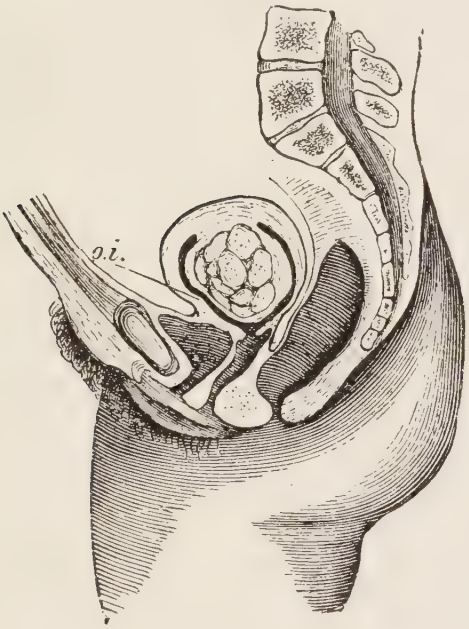

Submucous fibroid. (*Schroeder.*)

FIG. 45.

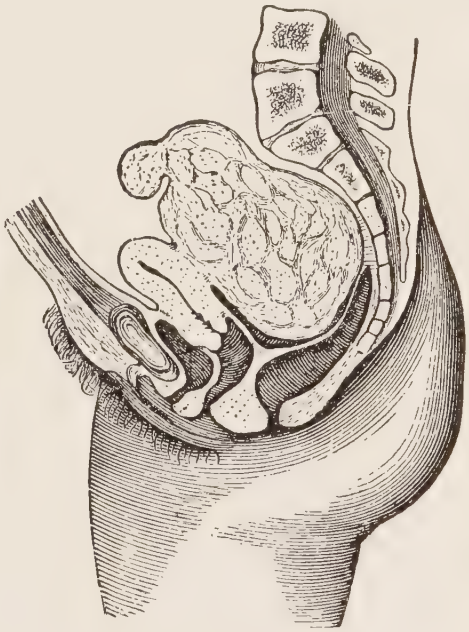

Subperitoneal Fibroid.

What changes may occur in fibroids?

1. They may undergo softening due to œdema or myxomatous degeneration, rarely fatty degeneration. By this softening fibrocysts may be formed.

2. They may undergo hardening, due to (*a*) atrophy, especially after the menopause, or removal of ovaries and tubes. The muscular tissue degenerates, and the fibrous tissue contracts. (*b*) Calcification, with the deposit of lime salts, beginning usually in the centre, sometimes at the periphery.

3. They may suppurate. This occurs most often in submucous fibroids, especially after instrumental traumatism; rarely in the subperitoneal variety after torsion of the pedicle.

4. Submucous fibroids may become more and more pedunculated, forming polypi. They are sometimes extruded from the uterus. Sometimes the capsule ruptures, and spontaneous enucleation occurs.

5. Cysts are formed by the softening of tissue and by the dilation of lymph-spaces.

6. Fibromyomatous uteri are occasionally the seat of carcinoma of their mucosa.

What changes occur in the uterus?

The muscular wall hypertrophies, especially in the submucous or interstitial varieties. The mucous membrane also hypertrophies, both in glands and connective tissue. Over the tumor the mucous membrane sometimes ulcerates.

FIG. 46.

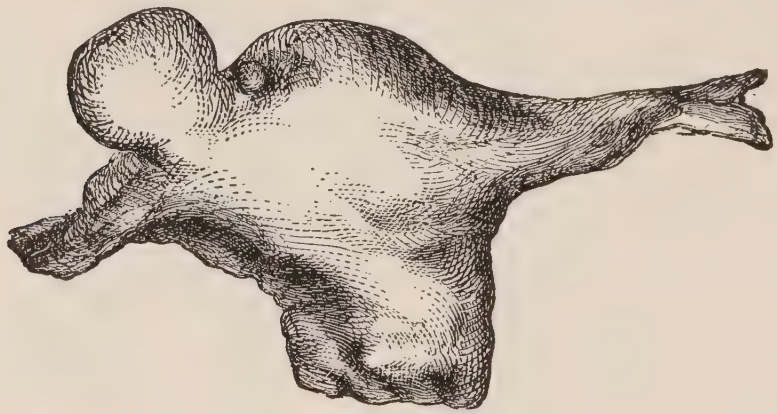

Subperitoneal Fibroid.

Changes in the position of the uterus are often produced :—

1. It may be drawn up into the abdomen.
2. It may be prolapsed.
3. It may be inverted, especially from submucous fibroids attached to the fundus.

Describe briefly fibroids of the cervix.

They, too, may be either interstitial, submucous or subperitoneal; they are usually hard and single.

The subperitoneal often grow out between the folds of the broad ligament.

The submucous and interstitial are apt to become pedunculated and form polypi. The interstitial fibroid of the cervix is sometimes mistaken for inversion of the uterus.

What are the symptoms of fibroid tumors of the uterus?

1. Hemorrhage.—First, menorrhagia, later metrorrhagia; delayed menopause; these occur especially in the submucous variety.
2. Pain.—(*a*) Dysmenorrhœa, chiefly in the submucous variety.
   (*b*) Pain due to pressure on the pelvic nerves or to peritonitis around the tumor.
3. Symptoms due to pressure:—
   On bladder, causing:—
   Irritability.
   Retention.
   Cystitis.
   On urethra, causing:—Difficulty in micturition.
   Perhaps retention.
   On ureter, causing:—Hydronephrosis.
   On rectum, causing:—
   Constipation.
   Diarrhœa.
   Sometimes tenesmus.
   Rarely complete obstruction.
   On pelvic nerves, causing:—
   Neuralgia.
   Numbness.
   On veins, causing:— Varicosities.
4. Sterility.
5. Abortion.

What are the physical signs?

Except in the case of some subperitoneal fibroids, the uterus is enlarged.

If within reach, a tumor is felt, harder than the muscular substance of the uterus, and movable with the uterus unless it is attached with a very long pedicle.

If it is a small fibroid in the cervix it may bulge into the vagina and resemble inversion of the uterus.

If it is a submucous fibroid, high up in the uterus, the sound may

detect it, but often it is necessary to dilate the cervix and introduce the finger.

If it is subperitoneal and on the anterior wall, a hard mass is felt in the anterior fornix moving with the uterus; the fundus may be felt behind it, and the sound on introduction does not pass into it.

If on the posterior wall, a hard mass is felt in the posterior fornix; the bimanual shows fundus in front of it, and the sound passes in front of it.

If it is a large fibroid extending into the abdomen, it is flat on percussion unless intestine overlies it; auscultation may detect the uterine souffle, especially at the sides, and the mass seems to belong to the uterus.

From what must you differentiate a fibroid tumor of the uterus?

Chronic metritis.
Flexions of the uterus.
Pregnancy.
Ovarian cyst.
Ectopic gestation.
Pelvic hæmatocele.
Inflammatory deposits.
Inversion of the uterus.

How would you differentiate a small fibroid tumor from chronic metritis?

Small Fibroid	*vs.*	*Chronic Metritis.*
Enlargement not uniform, usually hard irregularities.		Enlargement uniform.
Less sensitive.		More sensitive.
Os usually unaffected.		Os usually everted.

Both conditions may co-exist.

The differential diagnoses between fibroids and flexions of the uterus have already been given (see page 115, Fig. 23).

How would you differentiate a fibroid tumor from pregnancy?

Fibroid Tumor	*vs.*	*Pregnancy.*
Menstruation continues; usually increased.		Amenorrhœa is the rule.
Cervix not softened.		Cervix softened.

Later.

Absence of positive signs of pregnancy.	Positive signs present.

How would you differentiate a fibroid tumor from an ovarian cyst?

Fibroid Tumor	*vs.* *Ovarian Cyst.*
Hard and firm.	Soft and elastic.
More intimately connected with uterus.	Less intimately connected with uterus.
More central.	More lateral.
Menorrhagia common.	Menstruation normal or irregular; menorrhagia rare.

How would you differentiate a fibroid tumor from an ectopic gestation?

Fibroid Tumor	*vs.* *Ectopic Gestation.*
No menstrual period skipped.	Menstrual period or periods usually skipped.
Grows less rapidly.	Grows more rapidly.
More central.	More lateral.
More intimately connected with uterus.	Less intimately connected with uterus.
No decidual membrane cast off.	Decidual membrane cast off.
Absence of attacks of very severe sharp pain, with symptoms of collapse.	Such attacks occur.

How would you differentiate a fibroid tumor from a pelvic hæmatocele?

Fibroid Tumor	*vs.* *Pelvic Hæmatocele.*
Gradual development.	Rapid development.
Absence of acute symptoms.	Symptoms of sudden sharp pain, shock and hemorrhage.
Insensitive to pressure.	Sensitive to pressure.
Hard and firm.	First soft, later harder.
Moves with uterus.	Does not move with uterus.

How would you differentiate a fibroid tumor from a pelvic inflammatory deposit?

Fibroid Tumor	*vs.* *Inflammatory Deposit.*
Slow growth; no history of acute inflammation.	History of rapid development, and acute inflammation.
Moves with uterus, and seems a part of it.	Usually does not move with uterus, and seems less a part of it.
Insensitive to pressure.	Sensitive to pressure.

What is the prognosis of fibroid tumors?

It will depend on nearness to the menopause, rapidity of growth, pressure symptoms, and endometritis; the size of the tumor is of comparatively small importance, as a large one may produce few symptoms.

Death results from anæmia, sepsis, urinary disease complicating pregnancy, or intestinal obstruction.

What is the treatment?

A fibroid if small may give rise to no symptoms and need no treatment.

Treatment, if needed, may be (1) palliative or (2) curative.

Palliative Treatment.—(*a*) Drugs.—The administration of ergot alone or in combination with hydrastis may control the symptoms until the menopause is reached, when the tumor usually diminishes in size; the menopause, however, is often considerably delayed.

(*b*) Curettage.—If the symptoms are chiefly menorrhagia or metrorrhagia, a thorough curettage of the uterus, followed at intervals by astringent applications to the endometrium, will often give marked relief.

(*c*) Diminution of blood-supply.—Ligation of the uterine arteries from the vagina has proven of value in some cases, but is uncertain.

Tait's operation of removal of the ovaries and tubes has in many cases been not only palliative but curative; of late, however, it has been abandoned in favor of hysterectomy.

Curative Treatment.—This consists of either *myomectomy* or *hysterectomy.*

Describe the operation of myomectomy.

Myomectomy consists in exposing the tumor in the uterus, either from the abdomen or vagina, incising the capsule, enucleating the tumor, and closing its bed with catgut sutures.

This operation is indicated where the tumor can be easily removed without serious mutilation of the uterus. The operation is gaining in favor and may be employed even when the tumors are multiple.

What are the varieties of hysterectomy?

Hysterectomy, removal of the uterus, may be performed:

(*a*) Through the vagina—*vaginal hysterectomy*, indicated when the uterus and tumor are small.

(*b*) Through the abdomen—*abdominal hysterectomy*, indicated when the uterus and tumor are large.

Describe the operation of vaginal hysterectomy for fibromyoma uteri.

This differs from the operation described under carcinoma uteri only in the fact that in cases where fibro-myomata are large enough to cause symptoms the uterus with its tumors is often too large to come through the vagina without removing it piecemeal, *i. e.* by morcellation. After thorough disinfection of vulva and vagina, the uterus is curetted and irrigated with a sterile solution; the cervix is drawn down and separated from its vaginal attachments; the peritoneum is opened anteriorly and posteriorly and the uterine arteries are tied on both sides. If the uterus is too large to be removed as a whole, wedge- or disc-shaped pieces are removed from its centre or the uterus is divided in the median line and each half removed separately, care being taken to keep up traction on the uterus by volsellæ placed above the part to be removed. The broad ligaments are either ligated in section, or if more convenient during the operation, they may be clamped, and after the uterus is removed these clamps may or may not be replaced by ligatures according to the judgment of the operator. After the removal of the uterus, the pedicles are inverted into the vagina and sterile or iodoform gauze placed against them.

Describe the operation of abdominal hysterectomy for fibromyoma uteri.

The preceding operation, owing to the amount of technical skill

required and the difficulty in safely handling intestinal adhesions, has largely fallen into disrepute and given place to one of the two following forms of abdominal hysterectomy:

a. In one the cervix is removed—total extirpation. With this are associated the names Eastman, Martin, Chorbak, Polk.

b. In the other the cervix is left in the abdominal cavity—supravaginal hysterectomy. This is called Baer's method.

In both of these methods, after opening the abdomen, the broad ligaments are tied in section and cut close to the uterus.

In the total extirpation this ligation and cutting is continued down to the vagina: this is freed from the cervix and the whole uterus removed.

In the supravaginal hysterectomy (Baer) the ligation and cutting of the broad ligaments is continued until the cervix is reached and the uterine arteries are tied and cut; the uterus is then amputated at the cervix, and the latter is left, the vagina not being opened.

In each of these methods flaps of peritoneum are taken from the anterior and posterior surfaces of the uterus before its removal, and before closing the abdomen these flaps are brought together over the pedicles in the bottom of the pelvis.

Inversion of the Uterus.

What is the pathology?

In inversion, the uterus is turned more or less completely inside out (see Fig. 47).

It may be either—

1. Partial—where the depressed uterine wall does not extend beyond the os externum; or

2. Complete—where the inverted body, covered with mucous membrane, lies outside of the os externum, either in the vagina or between the labia.

The mechanism of production of the inversion is as follows:—

A portion of the uterine wall loses its tone, is depressed into the uterine cavity, usually by traction from below or abdominal pressure from above; the depressed portion is then grasped by the undepressed portion and forced toward or through the cervix.

The peritoneum follows the depression of the uterine wall, and lines the cup thus formed. The appendages may or may not lie within the cup.

The inversion occurring during the puerperium usually begins at the placental site ; when produced by intra-uterine tumors, it usually begins at the attachment of the tumor. The uterine mucous membrane is usually congested ; it may ulcerate ; sometimes it becomes gangrenous. Occasionally it becomes covered with squamous epithelium, and resembles skin.

Fig. 47.

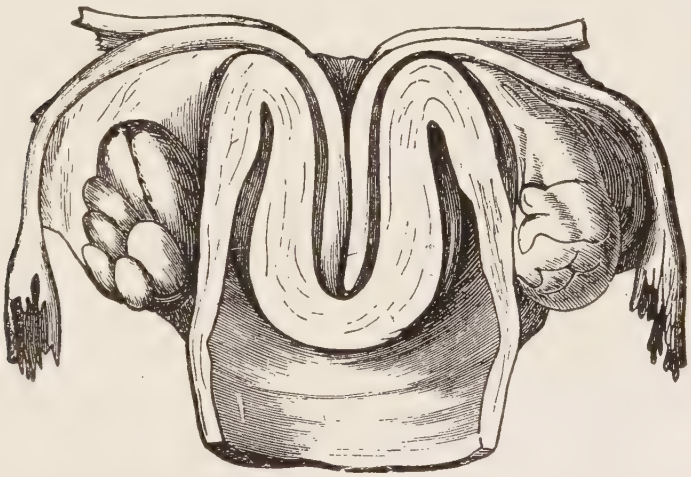

Inversion of Uterus (half-size, *Barnes* from *Crosse's* essay). The fundus lies in the vagina; the cervix is not inverted; the lips are flattened out to a swelling seen below the angle of inversion. The ovaries (seen from behind) are not in the peritoneal cup.

What is the etiology?

Inversion is predisposed to by—

(*a.*) Parturition.
(*b.*) Distention of the uterus from any cause.
(*c.*) Intra-uterine tumors.
(*d.*) Degeneration of uterine walls.

According to the time and cause of production, two varieties are recognized :—

1. Puerperal.—Produced during the puerperium, either by ab-

dominal pressure or mismanagement in the delivery of the placenta, especially the latter, traction on the cord being one of the most frequent causes.

2. Non-puerperal.—Secondary to intra-uterine tumors; especially pedunculated fibroids growing from the fundus.

The puerperal variety is much more common than the non-puerperal. The former is usually rapid in development; the latter gradual.

When the inversion is developed and reduced during the puerperium, it is called acute; otherwise, chronic inversion.

What are the symptoms?

At the time of the occurrence of acute inversion, there is pain, hemorrhage, shock, a feeling as of something giving way, and of fullness in the vagina.

This belongs especially to obstetrics.

The symptoms of the chronic inversion are hemorrhage, dragging pain in the pelvis, discomfort from the foreign body in the vagina, leucorrhœa, anæmia and general malaise. Rarely inversion exists with very few symptoms.

What are the physical signs?

These depend on whether the inversion is partial or complete, acute or chronic. In the partial variety the cupping may be felt by the hand on the abdomen, and the inverted portion detected by the use of the sound in the uterus. In the acute, complete inversion, one feels a soft, bulging tumor in the vagina or between the labia; it bleeds easily, is sensitive and smaller above where it is encircled by the cervix; it may or may not have the placenta attached to it. The sound passes around the tumor, but only a short distance into the cervix. The hand on the abdomen detects the absence of the fundus and the presence of the cervical ring. The physical signs of the chronic inversion are similar, save that the mass in the vagina is smaller, harder, and in the non-puerperal variety perhaps has attached to it the tumor which was its cause.

From what must you differentiate inversion of the uterus?

From polypi and prolapsus uteri.

How would you differentiate inversion of the uterus from a polypus?

The diagnosis of a complete inversion (see Fig. 48) from a polypus lying in the vagina (see Fig. 49) would be made as follows:—

Inversion	*vs.*	*Polypus.*
Fundus not felt in the abdomen; cervical ring felt.		Fundus felt in the abdomen.
Sound passes all around tumor, but only a short distance into the cervix.		Sound passes into the uterus, at the side of the tumor, more than $2\frac{1}{2}$ inches.

FIG. 49.

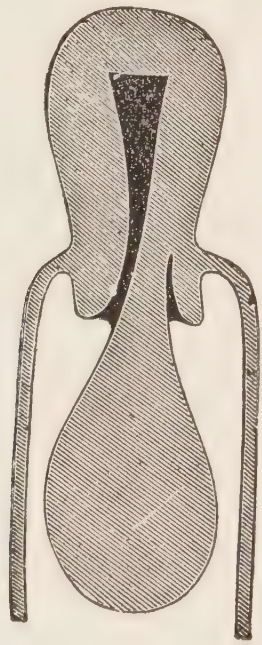

FIG. 48.

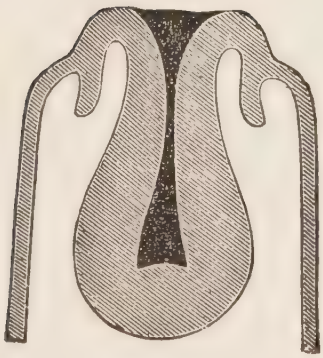

Inversion of Uterus (after Thomas). A cup-shaped depression is in the place of the uterus. Sound arrested at angle of flexion.

Uterine Polypus (after Thomas). The uterus in its normal position. Sound passes into uterine cavity.

The differential diagnosis between a partial inversion and an intra-uterine polypus (see Figs. 50 and 51) is often quite difficult. Careful examination by the ordinary bimanual and by the abdomino-rectal method may detect the cup-shaped depression of the partial inver-

sion. Enlargement of the uterus rather favors the diagnosis of polypus.

Both of these conditions may rarely coexist.

How would you differentiate inversion of the uterus from complete prolapse?

This rarely causes difficulty. It is made by finding in the latter the external os, the obliteration of the fornices, and by passing the sound into the uterine canal.

What are the results of an untreated inversion?

Very rarely it reduces itself. Rarely the patient suffers little inconvenience from it.

Usually the patient dies from hemorrhage or sepsis.

Fig. 50.

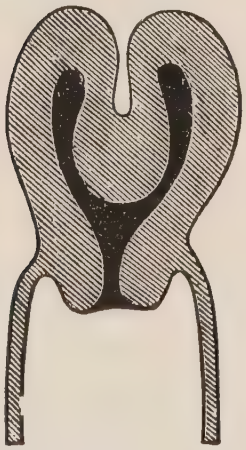

Partial Inversion of Uterus (after Thomas).

Fig. 51.

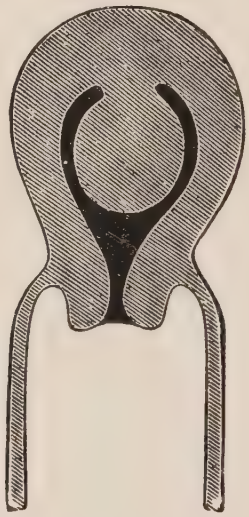

Polypus still Intra-uterine (after Thomas).

What is the treatment?

The object sought is the reposition of the fundus uteri.

Emmet's method (see Fig. 52) consists in inserting the right hand into the vagina, grasping the fundus in the palm, inserting the fingers into the cervix and pushing upward; at the same time separating the fingers as much as possible. The left hand meanwhile exercises through the abdomen counter-pressure on the cervical ring.

Noeggerath begins the reposition by dimpling in one horn of the uterus, and then uses this as a wedge to dilate the cervix.

Instead of the hand alone, cup-shaped repositors are often made use of.

In all these methods the patient is usually best prepared for the manipulation by the administration of prolonged hot-water douches, and the introduction of a vaginal elastic bag, to be distended with air or water, and worn twelve to twenty-four hours.

The manipulations are best performed under anæsthesia.

When the above methods fail, hysterectomy probably offers the best result.

Fig. 52.

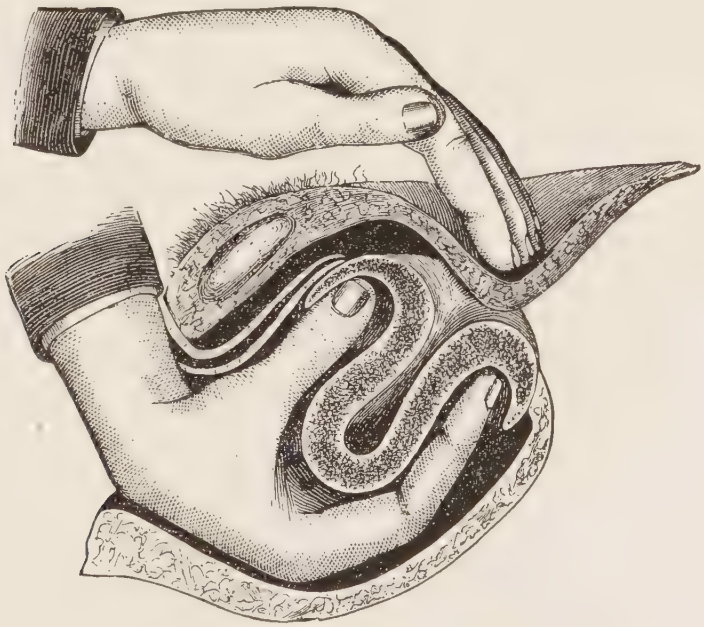

Reposition of the Inverted Uterus with the Hand alone (after Emmet).

Polypi.

What is meant by the term "uterine polypus," and what are the varieties?

A polypus is a pedunculated tumor attached to the uterine mucous membrane. The following varieties are recognized:—

1. Fibrous polypi.
2. Mucous polypi.
3. Pedunculated Nabothian follicles.
4. Placental polypi.
5. Papillomata of the cervix.

Describe briefly the fibrous polypi.

Fibrous polypi are submucous fibroids which have become pedunculated; at first lying within the uterus; later, dilating the cervix and becoming vaginal (see Fig. 53), sometimes even projecting beyond the vulva.

They spring from the muscular wall of the uterus, more often

Fig. 53.

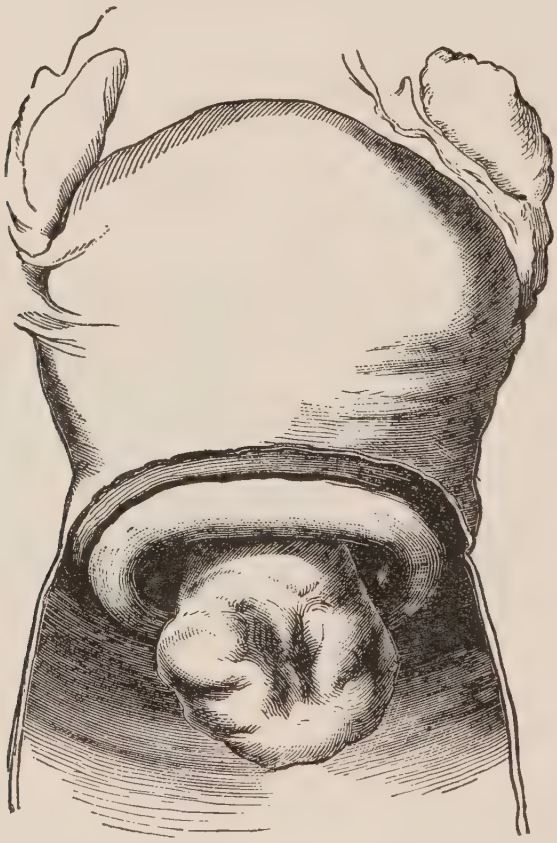

Intra-uterine Submucous Fibroid which is becoming Vaginal (*Sir J. Y. Simpson*).

from the body than cervix; they are composed chiefly of fibrous tissue with few blood vessels. Their presence sets up uterine contractions, which gradually expel them. Their shape is usually pyriform or ovoid.

Describe the mucous polypi.

These spring from the uterine mucous membrane, chiefly that of the cervix. There are usually more than one (see Fig. 54); they are

small, soft, vascular, and on section present the structure of mucous membrane.

What are the pedunculated Nabothian follicles?

They are the glands of the cervical mucous membrane which have become obstructed, formed retention cysts and assumed the polypoid shape.

What are placental polypi?

They are portions of undetached placenta which have received nutri-

Fig. 54.

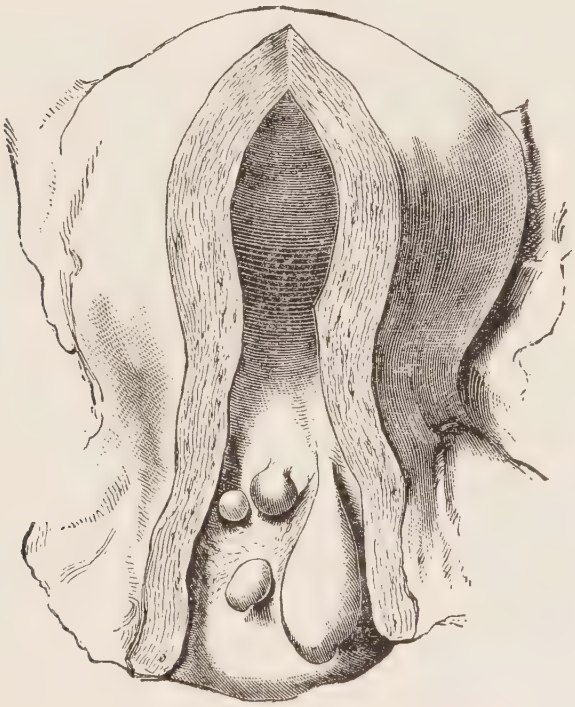

Group of Mucous Polypi growing in the Cervix Uteri (*Sir J. Y. Simpson*).

ment from their attachment to the uterus, have become coated with fibrin and so increased in size. By the uterine contractions they are made more pedunculated, and may be extruded from the cervix.

Describe the papillomatous variety of polypus.

Papilloma of the cervix is almost always either a malignant new growth or tends soon to become so. It is often called a "cauliflower excrescence" (Clarke), (see Fig. 55), is usually soft, friable, and bleeds easily.

What are the symptoms of polypi?

1. Hemorrhage.—First menorrhagia, then metrorrhagia, the source of the blood being the mucous membrane, which covers, or in the mucous variety forms, the substance of the polypus.
2. Leucorrhœa.—Due to the accompanying endometritis.
3. Pain.—Due to the efforts of the uterus to expel the tumor.
4. Sterility.—Due to the mechanical obstruction and to the endometritis.
5. Anæmia and general malaise.—Resulting from the foregoing conditions.

Fig. 55.

Cauliflower Excrescence growing from the Cervix Uteri (*Sir J. Y. Simpson*).

What are the physical signs?

When the polypus has passed the os externum, the finger in the vagina detects a pyriform or ovoid body, hard or soft according to the variety; it is movable and seems to come from the os. The use of the speculum determines its appearance.

If it is a fibrous polypus, the bimanual examination usually shows the uterus enlarged, and the sound proves the cavity elongated.

When the polypus is intra-uterine, the sound in some cases will detect its presence; in other cases dilatation of the cervix and introduction of the finger is necessary.

What is the treatment?

When the polypus is of considerable size and lies within or external to the os, the best treatment is removal by the wire écraseur, putting the wire loop as near the uterine attachment of the pedicle as possible.

Small polypoid projections may be scraped away with the curette; cervical polypi may usually be twisted off with the forceps.

When the polypus lies within the uterus, dilate the cervix and apply the écraseur.

If the pedicle is small, blunt, dull scissors may be substituted for the écraseur. If the pedicle is large or dilatation of the cervix is necessary, anæsthesia is to be employed.

All antiseptic precautions are to be used.

Carcinoma Uteri.

What is the pathology?

Carcinoma may begin in the cervix or body, being five times more frequent in the former. That of the cervix is of several forms. It may begin in the squamous cells of the vaginal surface; this is the epithelioma or cauliflower excrescence of the cervix. Microscopically it consists of plugs of epithelial cells extending deeply into the cervical tissue. Epithelial pearls, common in epithelioma of the skin, are rarely seen here.

Carcinoma of the cervical canal originates from the epithelium lining the canal or from that of the glands. These growths break down, forming necrotic ulcers with indurated edges. The vagina and body may become involved by direct extension and, through the agency of the lymphatics, the musculature and broad ligaments are involved. Involvement of lymph-nodes is a late occurrence.

Carcinoma of the uterine body arises from the lining epithelium of the cavity or from its tubular glands, and presents the appearances common to adeno-carcinomata. The occurrence of primary squamous-celled carcinoma of the body of the uterus is admitted by Amann and others. Carcinoma of the body is diffuse, circumscribed, or polypoid.

What is the etiology?

The etiology of cancer of the uterus is still unsettled. The factors which favor its development are age, heredity, parturition, laceration of the cervix, with erosion and depreciation of the vital powers.

1. *Age.*—It occurs most frequently between the ages of 40–50, but may occur as early as 25.

2. *Heredity.*—Although regarded as of less importance than formerly, its influence seems to be exemplified in some cases.

3. *Parturition.*—Frequent child-bearing apparently creates a marked predisposition.

4. *Laceration of the Cervix.*—Cancer of the cervix seems often to arise from a laceration, with erosion and cervical endometritis.

5. *Depreciation of the Vital Powers.*—Poor surroundings, poor food and air and hardships of any kind seem to predispose to cancer.

What are the symptoms?

1. *Hemorrhage.*—This is usually the first symptom. If hemorrhage occurs after the menopause, always suspect cancer.

2. *Offensive Discharge.*—Does not occur until ulceration begins.

3. *Pain.*—When the cervix is alone involved, pain is usually absent. When the disease has extended to the cellular tissue or peritoneum, or involves the body of the uterus, pain is common.

4. *Cachexia.*—This is always present to a greater or less extent in the later stages.

What are the physical signs?

If the disease affects the vaginal portion of the cervix, the examining finger detects a rough, ulcerated and indurated area, or perhaps a fungoid mass. On withdrawal, the finger is usually stained with blood and emits a foul odor. The speculum gives us the appearance of the growth.

When the cervical canal is the point of origin one may feel a nodular cervix or more commonly a hollowed out canal, the walls of which break down under the examining finger.

Carcinoma of the body of the uterus enlarges it and may be detected by the sound.

What is the prognosis?

It is better in cancer of the corpus uteri than of the cervix, but is bad in both. Many have passed the operable stage when first applying for treatment. It can be improved by earlier diagnosis made by microscopical examination of curettings in all suspected cases.

What is the treatment of carcinoma of the uterus?

1. *Radical.*—

When the disease is limited to the uterus, either cervix or body, vaginal hysterectomy is indicated. Aside from the appearance of the diseased area viewed through a speculum, the mobility of the uterus largely determines whether or not the disease has extended

beyond it. If the uterus is fixed in the pelvis, hysterectomy is usually contraindicated.

The combined abdominal and vaginal method offers some advantages. Werder ligates both broad ligaments through the abdomen, and continues his dissection downward till the upper part of the vagina is separated from its attachments.

The patient is then put into the lithotomy position, a circular incision is made through the vaginal wall some distance below the cervix, and the mass, consisting of uterus, appendages, and part of the vagina, is removed through the vagina.

2. *Palliative.*—When a radical operation is contraindicated, the following methods of treatment are of value :—

If hemorrhage is a marked symptom, and sloughing masses are present at the seat of ulceration, thoroughly curette the surface and apply carbolic acid, iodized phenol, or a solution of chloride of zinc. Frequent insertions of iodoform gauze soaked in a 4 per cent. solution of chloral will be found to act as an antiseptic and anæsthetic to the ulcerated surface.

For the foul discharges, vaginal douches of a weak solution of creolin are valuable.

The pain and distress in the later stages demand opium.

Attention to the general health is of course indicated.

Describe briefly the operation of vaginal hysterectomy.

Different operators differ somewhat in the details of the operation. The main features of the operation are as follows: The vulva is shaved, and the vagina and vulva thoroughly disinfected. The uterus is drawn down and held by an assistant; a semicircular incision is made around the cervix in the anterior fornix, and the cervix is separated from the bladder up to the utero-vesical pouch of the peritoneum. The cervix is drawn forward and the posterior fornix opened by a semicircular incision about the cervix, which is then freed up to the pouch of Douglas. The pouch of Douglas may now be opened, and a clean sponge with a long piece of silk attached, introduced to keep back the intestines. The uterus is freed from the lower portion of the broad ligaments by ligaturing in section, and then cutting with scissors close to the uterus. The latter may now be retroverted through the opening in the pouch of Douglas, and freed from the upper portion of the broad ligaments

by ligaturing, and cutting close to the uterus. It is well to draw the ovaries into the ligature, so that they will be removed with the uterus. The anterior reflection of peritoneum may now be divided, or, as practiced by many operators, this may be done before retroverting the uterus. All hemorrhage is checked and the parts are cleaned; the peritoneum is stitched to the vaginal wall; and a single suture unites the anterior and posterior vaginal walls in the median line. Two small strips of iodoform gauze are placed in contact with the stumps of the broad ligaments and their ends brought out through the vagina.

Some use clamps throughout the operation instead of ligatures.

Sarcoma of the Uterus.

What is the pathology?

Sarcoma of the uterus is a growth usually originating in the connective tissue of the mucosa and early appearing as a diffuse infiltration of it, and later extending to the uterine muscle. It may, however, begin as a nodule in the muscular wall. It usually affects the body of the uterus, being rare in the cervix. The masses are usually grayish in color, soft and brain-like; occasionally the circumscribed masses are firm and resemble fibroids, but have no capsule. They usually do not ulcerate as rapidly or deeply as carcinoma, but form larger tumors, and metastases are less common.

What is the etiology?

Little is known concerning it. It is most frequent between the ages forty to fifty, but, unlike carcinoma, often occurs in nulliparous women.

What are the symptoms?

1. Hemorrhage.
2. Watèry discharge.
3. Pain.
4. Cachexia.

Thus the symptoms are similar to those of carcinoma. Some authors claim, however, that the discharge is less offensive than in carcinoma, because there is less tissue necrosis.

What are the physical signs?

The uterus is usually enlarged; the sound, when introduced, detects great irregularity of the endometrium, and usually causes bleeding. If the curette is used, a grayish, brain-like material is removed.

With what are sarcoma and carcinoma of the body of the uterus most likely to be confused, and how is the diagnosis made?

They are chiefly to be confused with villous endometritis, sloughing polypi or retained secundines. The diagnosis is made by removing fragments with the curette, knife or scissors, and subjecting them to microscopical examination. Marked anæmia and emaciation would lead one to suspect malignant disease, yet severe endometritis or a vascular polypus may cause similar symptoms.

What is the treatment?

Hysterectomy gives us the only prospect of cure.

The palliative treatment consists in curetting and applying caustics to the interior of the uterus, keeping the vagina clean with antiseptic douches, as weak creolin, and relieving pain with opium.

Deciduoma Malignum.

What are its synonyms?

Chorio-epithelioma, decidual celled sarcoma, and syncytial carcinoma. These terms have been applied to a fairly well defined group of cases of malignant uterine disease, whose pathological appearances have varied somewhat in different cases.

Give its pathology.

The tumors consist of masses of cells often surrounding spaces filled with blood and fibrin. The cells are round, spindle, or polygonal, depending on how closely they are packed together. Furthermore they contain irregular masses or streaks of protoplasm with nuclei scattered through them, but with no division of the protoplasm into cells. Different writers have thought that they originate in the following structures:

a. Decidual cells; hence a tumor of maternal connective tissue origin; a deciduoma.

b. Langhans' layer of cells of the chorionic villi; hence fœtal in origin; a chorio-epithelioma.

c. The syncytial layer of the villi. This is the prevalent view and is based on the close resemblance of the protoplasmic masses in the tumor to syncytium. Syncytium is an epithelial structure, but whether maternal or fœtal is disputed.

Give its course and symptoms.

It occurs most often between the age of twenty and thirty-five years. It always follows a pregnancy, and in nearly half the cases has followed hydatidiform mole. Hemorrhage, watery discharge, and pain rapidly appear. Metastases are early and numerous. The vagina and vulva are often involved by extension or metastasis, and before death a number of abdominal and thoracic organs will show tumors whose microscopic appearances closely imitate those of the uterine growth. Death will follow, as a rule, within six months of the termination of the preceding pregnancy.

What is the treatment?

If a diagnosis can be made, with the help of the microscope, before metastases have occurred, immediate hysterectomy is indicated.

Salpingitis.

What is the pathology?

In salpingitis there is usually first a catarrhal or suppurative inflammation of the mucous membrane of the tube; this, extending to the peritoneum, sets up a localized peritonitis which usually closes the fimbriated extremity, and often by adhesions distorts the tube. From the closure of the outer extremity and the narrowing of the lumen in different places by the traction of peritonitic adhesions, the secretions are retained and distend the tube. This distention is favored by the softening arising from the inflammation. Other portions of the tube may be thickened, partly from inflammation of the tube itself and partly from the neighboring peritonitis. The closure of the abdominal ostium is accomplished either by an

adhesion to adjacent structures or the swelling of the muscular ring at the outer end of the tube constricts it; the swollen fimbriæ are thus compressed, then adhere and retract into the tube, or rather they remain of the same length and the swollen muscular wall extends out over them. The uterine ostium, as a rule, is made completely impermeable by the swelling of the tube, but is not obliterated.

The varieties of salpingitis, named according to the tubal contents, are—

1. Hydrosalpinx.
2. Hæmatosalpinx.
3. Pyosalpinx.

What is the etiology of salpingitis?

It usually arises from an extension to the tube of an inflammation of the endometrium, and its etiology is that of the endometritis, especially—

1. Sepsis during parturition or abortion.
2. The use of septic instruments.
3. Gonorrhœa.

What is the bacteriology of salpingitis?

The normal tube is free from bacteria. The most frequent inciter of salpingitis is the gonococcus, after this organism and about in the order of frequency in which they are found are the tubercle bacillus, streptococcus, staphylococcus, bacterium coli commune, and pneumococcus. Mixed infection is very rare. After a time bacteria die out in a pyosalpinx, so that a majority of such tubes examined have been found sterile.

What are the characteristics of a hydrosalpinx?

In a hydrosalpinx the tube is distended with serum, the result of a catarrhal inflammation. The softening of the walls easily allows the distention, which varies in position according to the traction of peritonitic adhesions. Hydrosalpinx is occasionally associated with fibroids of the uterus and is probably not then of bacterial origin.

What are the characteristics of a hæmatosalpinx?

Here the tube is distended with blood, which may have one of three sources:—

1. It most often occurs as a result of a tubal pregnancy.

2. It may be exuded from the tubal mucous membrane as a result of the catarrhal inflammation.

3. It may occur as an extension of a hæmatometra due to atresia of vagina or cervix.

The tube is usually first hypertrophied, later thinned, and it may rupture; this accident is usually delayed by peritonitic thickening about the tube. The blood is generally thick and tarry.

What are the characteristics of a pyosalpinx?

The tube is usually more thickened and surrounded by more peritonitic adhesions than is hydrosalpinx.

The pus may be slight in amount, or the tube may be immensely distended with very fetid pus.

The mucous membrane of the tube may be fairly well preserved and the seat of suppurative inflammation, or may be replaced by granulation tissue. Pus-tubes may be drained by rupture into hollow viscera or intraperitoneal rupture may occur, resulting in pelvic abscess or general peritonitis.

What are the symptoms of salpingitis?

The patient usually suffers from a burning and dragging pain in the region of the affected tube, especially on standing and walking. Dysmenorrhœa is common; repeated attacks of peritonitis are not infrequent. In the case of pyosalpinx septic symptoms may be present. There is tenderness on pressure in the lateral vaginal fornix, and on making a bimanual examination an elongated cystic mass can usually be detected at the side of the uterus.

What are the results of salpingitis?

A hydrosalpinx or hæmatosalpinx occasionally subsides so as to cause few symptoms; they may become purulent and form pyosalpinx.

A hæmatosalpinx may rupture into the peritoneum or into the broad ligament, forming an hæmatocele in the former case, and a hæmatoma in the latter.

A pyosalpinx if unrelieved by operation may continue for years, producing chronic invalidism, or may rupture and cause septicæmia or peritonitis.

What is the treatment of salpingitis?

1. *Prophylactic.*—Cleanliness and antisepsis during the puerperium and in the use of all instruments.

2. *Palliative.*—During the acute stage of invasion, rest in bed, poultices, laxatives, and, if much pain is present, allow opium.

When the case becomes subacute, *i. e.*, when fever has entirely subsided, apply counter-irritation to vaginal fornix over the affected tube or tubes, and employ tampons of boric acid and glycerine and hot-water vaginal douches.

3. *Radical.*—If the distention and thickening of the tube fail to subside under the foregoing treatment, remove the tube and ovary of the side affected. Often both sides are involved and require removal. A salpingitis is often favorably effected by curetting the uterus.

Tubercular Salpingitis.

Give its pathology.

The infection may reach the tube either through the blood, lymph-channels, endometrium, or peritoneum. It is usually secondary to a general, pulmonary, or peritoneal tuberculosis. Rarely the bacilli enter through the vagina and thus cause a primary genital tuberculosis. The tubes are much more frequently affected than other parts of the genital tract. The tubercular lesions are most marked near the abdominal ostia, and both tubes are, as a rule, affected.

Williams describes three varieties:

1. Miliary tuberculosis.
2. Chronic diffuse tuberculosis.
3. Chronic fibroid tuberculosis.

The abdominal ostia may or may not be occluded. The tubes vary in their degree of distention with pus or cheesy material. The lesion may be confined to the mucous membrane or involve the entire thickness of the tubal wall.

What are the predisposing causes?

The disease occurs from infancy to old age, but is most frequent between the ages of twenty and forty, and seems predisposed to by child-bearing and the puerperal state. It has followed sexual intercourse when the male genitals were tubercular.

Upon what would you base a diagnosis of tubercular salpingitis?

Absence of other causes of pyosalpinx, as gonorrhœa or infection following labor or abortion.

Evidence of other tubercular lesions.

Pallor, emaciation, and cough.

Physical examination, as a rule, reveals two large sausage-shaped masses lying close to the uterus, firmly adherent and less sensitive than is the rule with pyosalpinx.

Presence of tubercle bacilli in the uterine discharge.

What is the treatment?

The usual climatic and medicinal treatment of tuberculosis. In many cases this is the only treatment. If, however, the tube or tube and peritoneum alone are tuberculous, cœliotomy is indicated. The ovaries and tubes are removed and with them the uterus. The cervix may be left, as it is rarely diseased. The abdominal incision is closed without drainage.

Affections of the Ovaries.

Hemorrhage into the Ovaries.

Discuss briefly.

A small amount of hemorrhage into a follicle at the time of rupture is normal. Interstitial hemorrhage or apoplexy of the ovary, as it is called, results from congestion due to general circulatory disturbances or local inflammations. When hemorrhage occurs there is pain, and if hemorrhage is excessive, which is rarely the case, the symptoms may resemble those of a ruptured ectopic gestation.

Ovaritis.

What is the pathology?

Ovaritis or inflammation of the ovary may be acute or chronic.

Tubercular ovaritis is usually described separately.

Acute ovaritis may be follicular or interstitial; the two are often combined. In the follicular form, the epithelium of the follicles degenerates, the liquor folliculi becomes purulent, and the ovum is destroyed.

In the interstitial form, the stroma is infiltrated with serum and leucocytes and the connective tissue cells are increased; abscesses often form between the bundles of fibers; sometimes gangrene occurs.

Chronic ovaritis, often the result of the acute, may exhibit 3 forms—

1. The atrophic.
2. The hyperplastic.
3. The cystic.

In the atrophic form the ovary is small, hard, and nodular; the tunica albuginea is much thickened.

In the hyperplastic form, the ovary is enlarged, hard, and comparatively smooth; it usually prolapses from the increased weight.

In the cystic variety, the change is not confined to the follicles, but the stroma is involved as well.

The atrophic form may be present in one part of the ovary and the hyperplastic in another; the tunica albuginea is thickened and prevents rupture of the cysts. Ovaries the seat of ovaritis are often more or less surrounded by peritonitis.

What is the etiology of ovaritis?

It occasionally occurs in severe cases of the infectious diseases or metallic poisoning, but is most often secondary to disease of the tubes or peritoneum. It is predisposed to by anything causing congestion of the ovary, such as displacement of the uterus or ovary or excessive venery. A salpingitis with its own etiology is the most frequent cause of ovaritis. Among individual causes, the following are especially to be mentioned:—

Sepsis during labor, abortion or operations.
Gonorrhœa.
Catching cold during menstruation.

What are the symptoms?

The symptoms of acute ovaritis are usually mingled with those of the accompanying salpingitis or peritonitis. There is generally sharp pain in the ovarian region or regions, radiating to the back; often pain in micturition and defecation, and various reflex neuroses. If an abscess forms, septic symptoms may be present.

In the chronic form the symptoms are usually less marked; there

is dull pain in the ovarian region, increased by walking. There is dyspareunia and, especially if the ovary is prolapsed, painful defecation.

What are the physical signs?

These may be obscure, from the fact that the ovary and tube are bound together by peritonitic adhesions into one indistinct mass.

When definable, we feel, on making a bimanual examination, a round body at the side of the uterus, but separated from it by a slight interval; it is sensitive to pressure, producing pain of a sickening character; it may or may not be movable. When the ovary is prolapsed, this round, tender mass may be felt in the pouch of Douglas.

From what must you differentiate an inflamed ovary?

From— Salpingitis.
Peritonitic deposit.
Exudation into the broad ligament.
Fibroid tumor.
Fæces in the rectum.

How would you differentiate ovaritis from salpingitis?

This is often very difficult, from the fact that the two conditions frequently coexist. The chief features in the differential diagnosis are found in the physical signs, as follows:—

Ovaritis	*vs.* *Salpingitis.*
Lies farther from the uterus; more globular in shape.	Lies nearer the uterus; more elongated.
The ovary cannot be felt elsewhere.	The ovary can often be felt separate from the mass.
More sensitive.	Less sensitive.

How would you differentiate an ovaritis from an exudation in the broad ligament?

Ovaritis	*vs. Exudation in Broad Ligament.*
More circumscribed.	Less circumscribed.
Less closely related to vaginal vault.	More closely related to vaginal vault.
Less fixity of the uterus.	More fixity of the uterus.

How would you differentiate ovaritis from a lateral uterine fibroid?

Ovaritis	*vs.*	*Lateral Fibroid.*
Sensitive to pressure.		Insensitive to pressure.
Less intimately connected with the uterus.		More intimately connected with the uterus; moves with it.
Density less.		Density greater.
Menorrhagia less common.		Menorrhagia more common.

How would you differentiate ovaritis from fæces in the rectum?

Ovaritis	*vs.*	*Fæces.*
More sensitive.		Less sensitive.
Globular.		Elongated in shape.
Does not indent on pressure.		Indents on pressure.
Found after emptying rectum.		Disappears on emptying rectum.

What is the treatment of ovaritis?

During the acute stage keep patient quiet in bed; apply hot poultices to the lower abdomen; keep bowels open and fæces soft; give an anodyne, if necessary. Later, apply counter-irritation by means of iodine to the vaginal fornix over the affected organ, and support the ovary with a tampon. An excellent method is to soak a roll of gauze in a solution of iodoform 1 part, chloral 1 part, and glycerine 4 parts, and place this about the cervix, especially on the affected side. After the withdrawal of this support, which may be left in twelve to twenty-four hours, a hot-water vaginal douche may be used with advantage.

As a last resort, after a faithful trial of the above palliative measures for months without avail, and if the patient is a great sufferer, removal of the offending organ is indicated.

If abscess of the ovary is present, early operation is indicated.

An ovary the seat of ovaritis may be removed through the vagina.

Prolapse of the Ovary.

What is the etiology and pathology?

Prolapse of the ovary may occur either as a result or cause of disease. From the increase in size, due to congestion or inflammation, the ovary is apt to prolapse.

In a retroversion or retroflexion of the uterus, the ovaries also are usually drawn backward, and from their disturbed circulation become congested and diseased. In their descent they usually first lie on the retro-ovarian shelves, and may then further descend, especially the left, into the pouch of Douglas.

What are the symptoms?

They are those of ovaritis and of ovarian compression; the latter being most marked, viz.: painful defecation and dyspareunia. (The differential diagnosis has been given under ovaritis.)

What is the treatment?

(*a*) *Palliative.*—If due to a displacement of the uterus and both uterus and ovaries are movable, replace the uterus and maintain it in position by means of a pessary.

When the ovary alone is displaced, if movable, support it at first with a tampon; later a pessary may perhaps be worn.

When the ovary is fixed by adhesions, an attempt should be made to cause resolution of the adhesions by counter-irritation, glycerine or boroglyceride tampons, hot-water douches and gentle massage.

(*b*) *Radical.*—If the palliative measures fail and the symptoms are severe, operation is indicated, either to remove the prolapsed ovary, or, if the uterus is displaced backward, to break up the adhesions and fasten the uterus forward by hysterorrhaphy or by shortening the round ligaments.

Tumors of the Ovary.

What are the chief causes of enlargement of an ovary?

(*a*) Inflammation.
(*b*) Cysts.
(*c*) Papilloma.
(*d*) Carcinoma.
(*e*) Fibroma.
(*f*) Sarcoma.
(*g*) Tuberculosis.

Discuss ovarian sarcoma and fibroma.

Sarcomata are chiefly of the round-celled variety, but may be

spindle-celled. They occur at all ages, and not infrequently in children: both ovaries are often affected, and they frequently give rise to ascites. Hemorrhagic cysts may be formed in the large ones.

Fibromata, as a rule, are not so large as sarcomata, grow slowly, and do not cause ascites.

Discuss ovarian papilloma and carcinoma.

Papillomata occasionally originate on the surface of the ovary, but more begin in the wall of a cyst, whose wall they penetrate and then spread over the ovary and peritoneum. They resemble warts elsewhere, and may be the starting point of carcinoma.

The ovaries become the seat of carcinoma rarely primarily, but often from extension or metastasis. A cyst-adenoma or ovarian papilloma may become carcinomatous.

What are the varieties of ovarian cyst? Describe them.

The varieties of ovarian cyst are—

Corpus luteum cyst.
Simple follicular.
Cyst-adenoma.
Proliferating papillary.
Dermoid.

Corpus luteum cysts rarely attain the size of a child's head. They have no epithelial lining and contain thick brown fluid, whose color is derived from blood-pigment.

The simple follicular cysts are often multiple, and originate in distended Graafian follicles. They are lined by a single layer of epithelium and contain clear serous fluid.

The cyst-adenomata of the ovary form its largest cysts. They are the ordinary multilocular cysts, and may attain a very great size. They are adenomata whose alveoli become distended with fluid, and by breaking through of partition walls, cavities of several quarts' capacity are formed. Protruding into the larger loculi several smaller "secondary" or "daughter" cysts are often seen. Their fluid is viscid, gelatinous, sometimes blood-stained, and contains pseudomucin.

The proliferating papillary cysts: Any ovarian or parovarian cyst may have warty growths on its inner surface, but there is a variety of cyst which usually contains them and is thought to originate in the portions of the Wolffian ducts which are imbedded in the hilum

of the ovary. The presence of ciliated epithelium in many of them makes this origin probable.

The dermoid cyst on its interior seems lined with skin. It may contain hair, sebaceous matter, teeth or irregular fragments of bone, etc.

The present accepted idea as to the origin of dermoid cysts is that they are caused by an abnormal inclusion of the epiblast; *i. e.*, that certain misplaced embryonic cells grow within the ovary and produce the tissue to which they were destined.

What is the etiology of ovarian cysts?

Concerning this little is known. They occur most frequently between the ages of 20–50, but are found both in the young and old.

Simple ovaritis or injury of the ovary are said by some to predispose to the formation of a cyst.

What changes may occur in an ovarian cyst?

The principal changes are the following:—

It may rupture, usually from traumatism.
Hemorrhage may occur into it.
It may become gangrenous or may suppurate.

The hemorrhage, gangrene and suppuration are usually the result of torsion of the pedicle.

Suppuration may also arise from the introduction of sepsis if the tumor is tapped, as formerly practiced.

What are the symptoms of an ovarian cyst?

They are chiefly those of pressure. There may be difficulty in urination and defecation; in the later stages the patient is greatly exhausted by the great weight, and often suffers with dyspnœa

What are the physical signs of an ovarian cyst?

These vary with the location. When small and in the pelvis we get a tense elastic mass, usually fluctuating and insensitive to pressure. The multilocular variety may seem hard. The uterus is displaced by the tumor.

When the cyst has extended to the abdomen, we get distention of the abdomen and dullness on percussion over the tumor. Fluctuation can usually be detected.

What is the relation of ovarian cysts to the uterus?

When small the cyst prolapses from its own weight into Douglas'

cul-de-sac; hence the uterus will lie in front of the tumor. When the tumor is too large to lie in the pelvis it rises into the abdomen, the uterus then retroverts and lies under the tumor. Double ovarian cysts, even of large size, may continue to lie behind the uterus and displace it forward.

From what must you differentiate an ovarian cyst when small and situated in the pelvis?

From (*a*) Distended tube.
(*b*) Peritonitic exudation.
(*c*) Inflammatory exudation into broad ligament.
(*d*) Extra-uterine gestation.

How would you differentiate a small ovarian cyst from a distended tube?

Ovarian Cyst	*vs.* *Distended Tube.*
No inflammatory history; gradual development; little if any pain.	History of acute inflammation; pain usually prominent.
More globular.	More elongated.
Less intimately connected with the uterus.	More intimately connected with the uterus.
Insensitive to pressure.	Sensitive to pressure.
Less fixity.	More fixity.

How would you differentiate a small ovarian cyst from a peritonitic exudation?

Ovarian Cyst	*vs.* *Peritonitic Exudation.*
No history of acute inflammation.	History of acute inflammation.
Insensitive.	Sensitive to pressure.
More mobile.	Fixed.
More lateral.	Usually in pouch of Douglas.

How would you differentiate a small ovarian cyst from an inflammatory exudation into the broad ligament?

Ovarian Cyst	*vs.* *Inflammatory Exudation.*
Absence of history of inflammation.	History of inflammation following labor, abortion, or operation. If a hæmatoma, history of sharp pain, shock, perhaps symptoms of hemorrhage.

More mobile.	Fixed.
Induration of parametrium wanting.	Induration present.
Insensitive.	Sensitive to pressure.
Bulges less into vagina.	Bulges more into vagina.

How would you differentiate an ovarian cyst from an extra-uterine pregnancy?

Ovarian Cyst	*vs. Extra-uterine Pregnancy.*
Slow growth.	Growth more rapid.
No symptoms of pregnancy.	Constitutional symptoms of pregnancy.
Menstruation usually not far from normal.	Amenorrhœa usually followed by menorrhagia.
More mobile.	More fixed.
Uterus usually not enlarged.	Uterus enlarged.
Pain only from pressure; no acute attacks.	Attacks of pain; finally a severe attack, symptoms of shock and hemorrhage.

From what must you differentiate a large ovarian cyst occupying the abdomen?

From (*a*) Pregnancy.
(*b*) Ascites.
(*c*) Fibroid tumor of the uterus.
(*d*) Distended bladder.
(*e*) Hæmatometra.

How would you differentiate a large ovarian cyst from a pregnant uterus?

Ovarian Cyst	*vs. Pregnant Uterus.*
More lateral.	More central.
Menstruation continues.	Amenorrhœa the rule.
Positive symptoms of pregnancy absent.	Positive symptoms of pregnancy present.
Uterus small, separate from tumor; cervix not softened.	Uterus forms the tumor; cervix softened.
Fluctuating.	Less fluctuating; fœtal parts felt.

Intermittent contractions absent.	Intermittent contractions present.
Growth less rapid.	Growth more rapid.

How would you differentiate a large ovarian cyst from ascites?

Ovarian Cyst vs.	*Ascites.*
Patient on back :—	Patient on back :—
Swelling central or unilateral.	Swelling bilateral.
Dullness in front.	Tympanitic in front.
Tympanitic on the sides.	Dullness on the sides.
Percussion note varies little on turning patient from side to side.	Percussion note varies greatly in turning from side to side.
Circumscribed.	Diffuse.

How would you differentiate a large ovarian cyst from a large fibroid tumor of the uterus?

Ovarian Cyst vs.	*Fibroid.*
Fluctuating.	Firm, non-fluctuating.
Less intimately connected with the uterus.	More intimately connected with the uterus; moves with it.
Menorrhagia uncommon.	Menorrhagia common.
Uterus usually not enlarged.	Uterus usually enlarged.

How would you differentiate a large ovarian cyst from a distended bladder?

Ovarian Cyst vs.	*Distended Bladder.*
More lateral.	Central.
Enlargement slow.	Enlargement rapid.
Remains after patient is catheterized.	Disappears when patient is catheterized.

How would you differentiate a large ovarian cyst from a hæmatometra?

Ovarian Cyst vs.	*Hæmatometra.*
Menstrual flow appears.	Menstrual blood retained.
More lateral; separate from the uterus.	Central; tumor formed by the distended uterus.
Pain only from pressure.	Periodical attacks of pain, due to increase of contents.

Atresia absent.	Atresia of vagina or cervix present.

What is the treatment of an ovarian cyst?

The only treatment is removal. If large, through abdominal cœliotomy; if small, it can often be easily removed through the vagina.

Parovarian Cysts.

Describe briefly.

They are cysts developed in the broad ligament from the parovarium, the remains of the Wolffian body. These cysts are usually unilocular; the contents colorless, thin and watery. The cyst wall is usually thin, and fluctuation very distinct. As the cyst grows, it opens up the folds of the broad ligament, and obliterates the mesosalpinx. The Fallopian tube lies stretched out over its upper surface.

How would you distinguish between an ovarian and parovarian cyst?

Ovarian Cyst vs.	*Parovarian Cyst.*
Has a pedicle.	No pedicle.
Somewhat movable.	Deep-seated in pelvis and immovable.
Uterus in front when small; behind when large.	Uterus pushed to opposite side when small; forward against symphysis when large.

What is the treatment?

Removal by cœliotomy is the best treatment. The broad ligament, which is spread out over the tumor, is incised near to and parallel to the tube, and the tumor is enucleated from its bed. The cavity in the broad ligament is then either closed so as to leave no pockets, or the edges of the broad ligament are brought to and stitched in the lower angle of the abdominal wound and the cavity drained. The former practice is usually preferable.

What are the chief points in the technique of an abdominal cœliotomy for the removal of the uterine appendages or a cyst?

Have the bowels of the patient thoroughly emptied and let her take a thorough warm bath. On the evening before the operation, place upon the abdomen a towel soaked in a solution of soft soap to be left until the following morning. On the day of the operation, the abdomen and pubes are shaved, scrubbed with soap and water, washed with alcohol, and then with bichloride 1–1000.

All antiseptic precautions must be observed in regard to instruments, hands, sponges, etc.

The patient having been anæsthetized, a final cleansing of the abdomen with alcohol and bichloride is performed. An incision, about three inches long, is made in the median line, beginning just below the umbilicus; this incision is deepened to the peritoneum and bleeding points are clamped. The peritoneum is raised with thumb forceps, one held by the operator, the other by an assistant, and the peritoneum cut between the forceps; the incision is lengthened with the scissors, cutting on the finger to the length of the abdominal wound. The latter may be lengthened, if necessary.

If the operation is for the removal of the appendages, the fundus of the uterus is felt for as a landmark; the ovary and tube of the affected side are brought into the abdominal wound and surrounded by warm sponges or pads. The broad ligament is tied in section beneath the appendage and the parts outside the ligature cut away, leaving just enough to prevent the ligature from slipping. The first ligature should be placed external to the ovary including the infundibulo-pelvic ligament, which contains the ovarian artery. The ligature placed at the proximal end of the tube should include the anastomotic branch between the uterine and ovarian arteries. The ligature is then cut short and the stump dropped back into the abdominal cavity. The other side is treated, if necessary, in the same way.

If the operation is for an ovarian cyst, after opening the abdomen the cyst is punctured with a trocar, the emptied sac drawn out of the abdominal wound, the adhesions separated, if necessary, the pedicle tied, and the stump treated as before. If pus has gotten into the abdominal cavity, the latter is freely irrigated with warm sterilized salt solution; drainage may or may not be indicated.

The abdominal wound is closed by one of several methods. An ideal method is that which sutures each layer of the abdominal wall separately. A continuous catgut suture is used for the peritoneum, another for the aponeurosis, interrupted catgut sutures unite the subcutaneous fat, and the skin is united by any desired method of suture. The wound is then cleansed, a sterile dressing is applied and held in place by plaster strips and an abdominal binder, and the patient is transferred to bed. The bed should be warmed with hot-water bottles, but great care should be taken that the patient is not burned by them.

What is the after-treatment of the case?

The patient receives no food by the mouth for twelve to twenty-four hours, nutrient enemata being used if needed. After vomiting, due to the anæsthetic, has subsided, thirst is quenched by the repeated administration of small doses of hot water; later cool or carbonated water is given. The urine is drawn with a catheter. As little opium as possible is used. The bowels are moved on the third day by enema, calomel gr. iv (gr. j every half hour) or salines. If tympanites occurs at any time, the bowels are moved.

If silk or silk-worm gut sutures have been used they should be removed within a week. The patient is allowed up on the fourteenth to twenty-first day.

Describe the vaginal operation for the removal of a diseased appendage or an ovarian cyst.

The same preliminary preparations are observed as for an abdominal cœliotomy. At the time of the operation the vulva and vagina are thoroughly disinfected, the patient being in the lithotomy position and on a Kelly's pad. The perineum is retracted with a speculum. If endometritis is present the uterus is first curetted. The posterior lip of the cervix is then seized with a volsella and drawn forward. The vagina is grasped with a toothed thumb-forceps about where it joins the rectum, and drawn downward. Between this point and the junction of vagina and cervix a cut is made with scissors directed toward the uterus; first going through the vagina, then into the pouch of Douglas. This incision may be enlarged laterally. Two fingers are inserted into this opening and the pelvic

contents examined. If a diseased tube and ovary are found, a gauze pad or sponge, each with a long silk attached, is inserted above the mass to be removed, to keep back intestines or omentum; the appendage is freed, brought down into the vagina, ligated and removed. The gauze pad or sponge is now removed and the vaginal opening may either be closed or the pelvic cavity may be drained with gauze, according to the indications. If an ovarian cyst is to be removed, after opening the pouch of Douglas the cyst is tapped and emptied; the sac drawn down into the vagina, ligated, and removed.

What are the advantages and disadvantages of the vaginal as compared with the abdominal operation?

In the vaginal operation the shock is less and the abdominal cicatrix with its tendency to hernia is avoided.

The vaginal operation requires greater skill in operating; there are greater possibilities of injuring gut in separating adhesions, and greater difficulty in repairing the damage; it may be hard to locate and control bleeding. In some cases the appendages cannot be removed by vagina until after the removal of the uterus. Hence if there is doubt as to the diagnosis and a possibility that the whole or a part of an ovary or tube may be allowed to remain, the abdominal route is to be selected as favoring conservative surgery.

What are the indications for a vaginal operation?

In those cases in which the patient's condition will not warrant a severe operation, a pelvic abscess, pus-tube, or ovarian abscess may be drained through the vagina. Later, after recovery from sepsis, an abdominal operation may be performed with safety.

A small ovarian cyst or prolapsed ovary may be removed with advantage through the vagina, as may also a small fibroid in the lower uterine segment through either anterior or posterior fornix.

The vaginal route is to be selected for the drainage of any large collection of blood, serum, or pus in the pelvis, which is well walled off by intestinal adhesions. Vaginal hysterectomy is the operation usually done for carcinoma of the uterus.

What operations are performed through the anterior fornix?

Small fibroids of the cervix or anterior uterine wall are removed through the anterior fornix. This route is also employed for shortening the round ligaments.

How would you prepare catgut for ordinary ligature and suture?

One of the best methods is that by means of boiling alcohol. This is conveniently carried out by Dowd's apparatus a cut of which is here given. It consists of a coil of block tin tubing en-

Fig. 56.

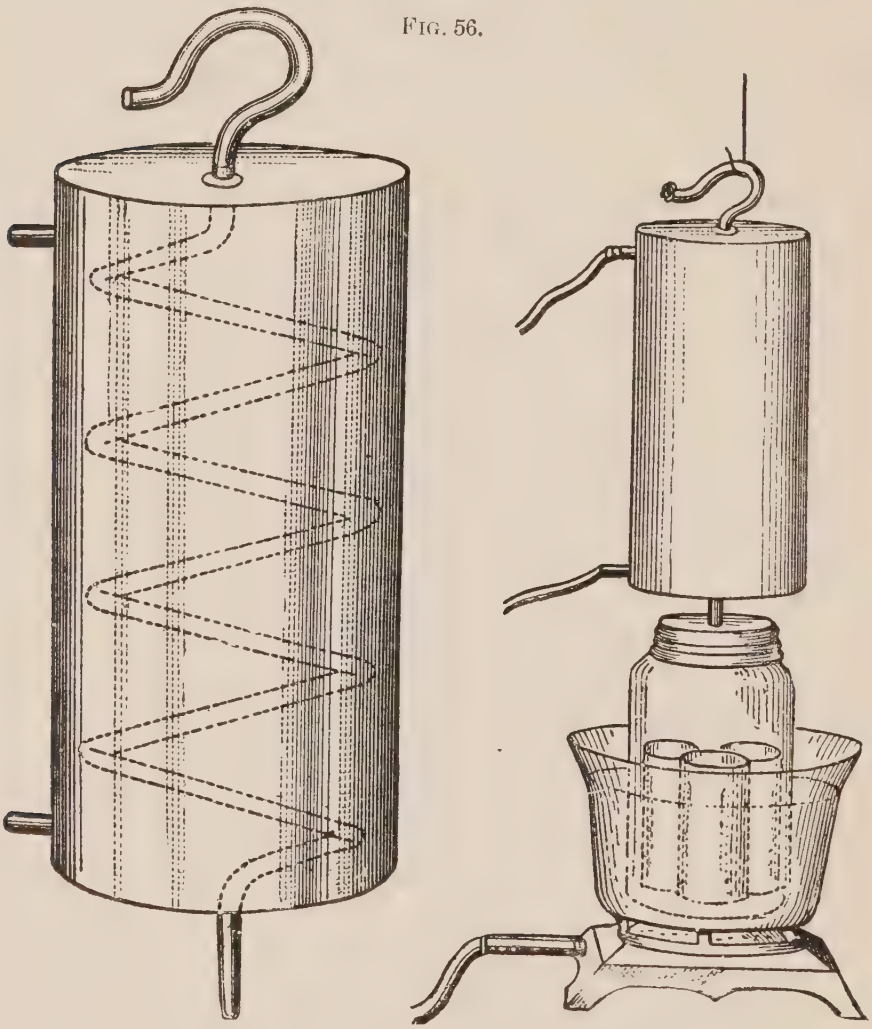

Dowd's Apparatus for Sterilizing Catgut.

cased in a copper cylinder. The lower end of the coil is straightened out and projects through the rubber cork of the jar in which the bottles of catgut are to be sterilized. The upper end of the coil is bent into a convenient shape for suspension and during use

is closed with a cotton plug. On one side of the cylinder are two taps, the lower for the entrance, the upper for the exit of cold water from a faucet which condenses the alcoholic vapor which rises in the coil.

The catgut, wound on glass spools, is placed in small bottles (preferably with screw tops) which are filled with strong alcohol. These bottles are placed in the large jar and covered with strong alcohol. The jar is then attached to the condenser, and placed in a vessel of water on a gas or other stove. The boiling is kept up for an hour.

Another good method is the following:—

1. Soak the gut in ether for 1 hour.
2. Wipe with a bichloride towel.
3. Soak in bichloride 1 : 1000 for 8 hours.
4. Wipe with a bichloride towel.
5. Store it in absolute alcohol.

How would you prepare the chromicized (McEwen's) catgut?

Soak the gut for 48 hours in the following solution:—

℞.	Acidi chromici,		℥iij–ʒ vss
	Aquæ,	q. s. ad	Oj
M. et adde			
	Glycerini,		Ov.

Then store the gut in carbolized glycerine 1–5.

Wipe with a bichloride towel before using.

Ectopic Gestation.

Ectopic gestation may be considered as primarily tubal. Three varieties are recognized:

1. Tubal proper, (free tubal).

2. Tubo-uterine, (interstitial); in that portion of the tube embraced by the uterine wall.

3. Tubo-ovarian.—Between the tube and the ovary, originally tubal.

Abdominal pregnancy was originally tubal. Ovarian pregnancy never occurs.

What is the etiology?

It has long been recognized that tubal inflammation, peritoneal adhesions, and pressure upon the tube predispose to tubal pregnancy. In the case of inflammations, however, not until the tubal mucosa has become practically normal is tubal pregnancy likely to occur. Hindrance to the passage of a fertile ovum into the uterus will not of itself cause tubal implantation of the ovum. An hypothesis has been advanced that under normal conditions the tube will not undergo the decidual change necessary for pregnancy, but that the tubal mucosa of a few women possesses the property, common in many of the lower animals, of responding to the stimulus which the fertilized ovum offers by forming a decidual membrane. In such individuals, if the passage of the ovum into the uterus is interferred with, tubal pregnancy results.

What are the symptoms?

There is usually a history of previous sterility; then symptoms of early pregnancy; usually amenorrhœa at first, later irregular menstruation or menorrhagia, with passage of portions of the uterine decidual membrane. Attacks of pain with symptoms of shock may be present; then when the sac ruptures, symptoms of hemorrhage, severe shock, and collapse.

What are the physical signs?

Before rupture occurs, the uterus is felt to be enlarged and softened, and at the side is found a mass formed by the distended tube.

At the time of rupture, if it has occurred with hemorrhage into the peritoneal cavity, very few physical signs may be present; simply an indistinct feeling of fluid in the pouch of Douglas. Later, as the blood coagulates, a tumor is formed behind the uterus.

If the rupture has occurred into the broad ligament, a tumor is formed at once by the blood-distended ligament. This tumor pushes the uterus forward and toward the opposite side. It tends to bulge into the vagina, and a finger introduced into the rectum detects a narrowing of it.

What is the course and result?

Ectopic gestation is primarily tubal. At about the third month, either a rupture of the tubal wall may occur, with the escape of the fœtal products, or the escape may take place through the fimbriated

extremity, constituting a tubal abortion. When a rupture of the tubal wall occurs, it may take place (1) through a portion covered by peritoneum, *i. e.*, into the peritoneal cavity, or (2) through a portion not covered by peritoneum, *i. e.*, down between the folds of the broad ligament. The intraperitoneal rupture may prove fatal, although often not until several hemorrhages have occurred. In an extraperitoneal rupture the hemorrhage is usually limited. The fœtus usually dies when it escapes from the tube. When the rupture, however, is extraperitoneal, *i. e.*, between the folds of the broad ligament, the fœtus may survive, being nourished by a placenta attached to the floor and walls of the pelvis or broad ligament, and go to term.

At any time after the middle of pregnancy the fœtal sac may rupture and the fœtus lie free in the peritoneal cavity. This constitutes secondary rupture and explains the cases of so-called abdominal pregnancy. Primary rupture may be delayed in the cases of interstitial pregnancy until the sixteenth week; hemorrhage is then likely to prove fatal.

When the blood effusion is small it may be absorbed. Sometimes suppuration occurs.

From what must you differentiate extra-uterine pregnancy?

Suppurative cellulitis.
Fibroid tumor.
Ovarian cyst.
Dermoid cyst.
Parovarian cyst.
Salpingitis.
Retroversio-flexio.

What is the treatment?

If a diagnosis is made before rupture occurs, the best treatment consists in the removal of the tube with its contents. At the time of rupture, if this has taken place into the peritoneal cavity, open the abdomen, ligate and remove the sac from which the hemorrhage comes, also the fœtal remains and blood clots. Drainage is rarely necessary, unless the fœtal sac has become infected.

If the rupture has taken place into the broad ligament and the resulting hæmatoma is small, this may be left with the hope of its absorption. If repeated hemorrhages occur, surgical interference

is indicated. If suppuration take place, the mass should be opened from the vagina and drained.

If the life of the fœtus continues after the rupture, and the case is seen during the early months, the life of the fœtus should be disregarded in the interest of the mother. The fœtus and membranes should be removed and the sac drained. If the case is first seen after the viability of the fœtus, an attempt should be made to save both lives.

Fistulæ.

What are the chief varieties met with in gynæcology?

They may be either urinary or fecal.

Urinary fistulæ present the following varieties (see Fig. 57):—

1. Urethro-vaginal.
2. Vesico-vaginal.
3. Vesico-uterine.
4. Uretero-vaginal.
5. Uretero-uterine.

The most common is the vesico-vaginal.

The fecal fistula which especially concerns us is the recto-vaginal.

What is the etiology of a vesico-vaginal fistula?

The most common cause is sloughing following long-continued pressure, usually in parturition, but occasionally from a pessary. It may be produced by direct laceration through the septum. It is predisposed to by a tedious labor.

What are the symptoms?

The involuntary escape of urine.

A urinous odor about the person.

Irritation and excoriation of the vulva and parts around.

How is the diagnosis made?

If the fistula is not evident on exposing the parts with a Sims' speculum, the patient being in Sims' position, the bladder may be distended with some colored antiseptic fluid, like creolin solution, and by the exit of the latter the fistula may be detected, and then verified by a probe.

What is the treatment?

The treatment usually pursued in this country is the operation of

Sims, which is performed as follows: The patient is anæsthetized, an antiseptic vaginal douche given, and all antiseptic precautions observed during the operation. She is placed in Sims' position and Sims' speculum introduced. The edges of the fistula are pared with the knife or scissors, the mucous membrane not being included in the incision. Silkworm-gut or silver-wire sutures are then introduced, about one-fifth to one-fourth inch apart, not penetrating the mucous membrane. The parts are brought into apposition by tying or twisting the sutures, and then a self-retaining catheter is introduced. The sutures are left for eight days. The operation for a urethro-vaginal fistula is similar to the above.

FIG. 57.

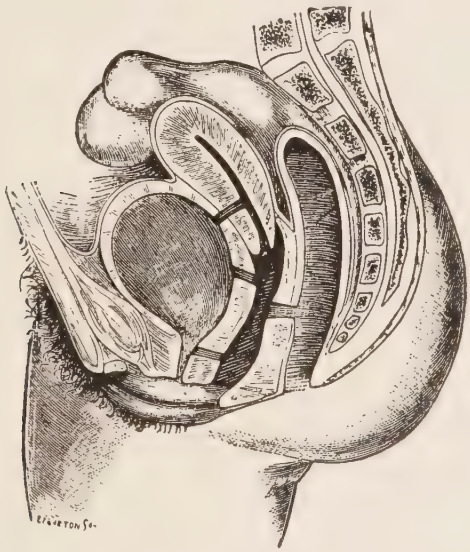

TO REPRESENT THE CHIEF VARIETIES OF URINARY FISTULA—URETHRO-VAGINAL, VESICO-VAGINAL AND VESICO-UTERINE.—Those with the ureters are not seen. The seat of a recto-vaginal fistula is indicated (*De Sinéty*).

What are the chief steps in the operation for the cure of a vesico-uterine fistula?

Emmet regards the condition as due to a laceration of the cervix extending into the bladder, the laceration healing only below. The operation is based on this idea, viz.: The cervix is split up to the fistula; the edges of the latter are denuded, and the whole brought together in a manner similar to a trachelorrhaphy, especial care being taken with the upper sutures.

Recto-vaginal Fistula.

What is the etiology?

This, like the vesico-vaginal fistula, is usually due to sloughing caused by long-continued pressure in parturition, or may be produced by laceration through the septum, either by the unaided efforts of nature or by instrumental delivery. Cancer or syphilis may, of course, cause fistula, but this will not concern us here.

What is the treatment?

It is similar to Sims' operation for vesico-vaginal fistula. The edges are denuded and brought together by silkworm gut or silver wire, the rectal mucous membrane being uninjured. If the fistula is near the vulva, it is usually best to divide the sphincter ani and perineum up to the fistula, to dissect this out, and then close the parts as in a laceration of the perineum through the sphincter ani.

INDEX.

Alexander's operation, 124
Amenorrhœa, 99
Anterior colporrhaphy, 139
Applicator, uterine, 59
Atrophy of the uterus, 156

Bacteria of endometritis, 147
of salpingitis, 181
of vagina, 84
Bimanual examination, 46
Bladder, 36
Bulbi vestibuli, 20

Carcinoma, ovarian, 189
uteri, 175
Catgut, preparation of, 198
Cellulitis, pelvic, 91
Cervical erosions, 149
Ciliæ, 32
Clitoris, 18
Coccygodynia, 81
Condylomata, pointed, 77
syphilitic, 78
Corpus luteum cyst, 189
Curette, 64
Cysts of ovary, 189

Deciduoma malignum, 179
Development of the pelvic organs, 43
Dilators, 59
elastic, 63
graduated, hard, 61
Displacements of the uterus, 113
anteflexion, 114
retroversion and retroflexion, 116
Dysmenorrhœa, 102

Ectopic gestation, 199
Eczema of the vulva, 75
Emmet's operation, 133
Endometritis, 147
acute, 147
chronic, 148
villous, 152
Erosions, cervical, 149
Erythema of the vulva, 75

Fallopian tubes, 31
Fibroid tumors of the uterus, 157
ovarian, 188
Fistula, recto-vaginal, 204
Fistulæ, 202
Follicular cysts, 189
Fornix, anterior, operations through, 197
Fossa navicularis, 20
Fourchette, 20
Fungosities, uterine, 152

Gonococcus, 66
Gonorrhœa, 67

Hæmatocele and hæmatoma, pelvic, 94
pudendal, 73
Hemorrhage from vulva, 74
Hernia, pudendal, 72
Hymen, 21
Hyperæsthesia of the vulva, 80
Hypertrophy of the cervix, 140
Hysterectomy, 165
vaginal, 177
Hysterorrhaphy, 126
Kelly's, 126

INSTRUMENTS, 48
Inversion of the uterus, 166
Irritable urethral caruncle, 82
Ischio-rectal fossa, 42

KELLY'S hysterorrhaphy, 126
Kraurosis vulvæ, 80

LABIA majora, 17
minora, 18
Laceration of the cervix, 142
of the perineum, 130

MALFORMATIONS of the uterus, 108
of the vagina, 106
atresia of, 107
stenosis of, 108
of the vulva, 83
Menstruation, 98
disorders of, 99
amenorrhœa, 99
dysmenorrhœa, 102
congestive, 103
membranous, 105
neuralgic, 104
obstructive, 102
ovarian, 104
menorrhagia and metrorrhagia, 101
vicarious, 100
Mesosalpinx, 30
Metritis, 153
acute, 153
chronic, 154
Mons veneris, 17
Myomectomy, 165

NEW growths of the vulva, 77

OVARIES, 32
affections of, 184
cysts, 189
enlargement of, 188
hemorrhage into, 184
prolapse of, 188
tumors of, 188
Ovaritis, 184

PAPILLOMATA, ovarian, 189
simple, 77
Parovarian cysts, 194
Parovarium, 35
Pelvic floor, 40
Perineal body, 41
Perineum, muscles of, 42
Peritoneum, pelvic, 87
Peritonitis, pelvic, 88
Pessaries, 121
stem, 63
Physical examination of pelvic organs, 43
Polypi, 71
Probe, uterine, 59
Prolapse of urethral mucous membrane, 83
Prolapsus uteri, 127
Pruritus vulvæ, 78
Pudendal hæmatocele, 73
hernia, 72

RECTAL examination, 47
Rectum, 38
Round ligaments, intra-abdominal shortening of, 127

SAENGER-TAIT operation, 134
Salpingitis, 180
tubercular, 183
Sarcoma of the uterus, 178
ovarian, 188
Skin diseases of the vulva, 75
Sound, uterine, 55
Specula, 48
Brewer's speculum, 52
Fergusson's speculum, 51
Kelly's speculum, 53
Simon's speculum, 51
Sims' speculum, 49
Stem pessaries, 63
Stenosis of the cervix, 142
of the vagina, 108

TENTS, 58
Theca folliculi, 33
Trachelorrhaphy, 145

URINARY tract, 35

Uterine applicators, 59
fungosities, 152
Uterus, 23
mucous membrane of, 25
changes of, 26

Vagina, 21
bacteria of, 84
diseases of, 84
secretions of, 22
stenosis of, 108
Vaginal examination, 44
Vaginismus, 80
Vaginitis, croupous, 87
gonorrhœal, 86
simple catarrhal, 84
Vaginitis, ulcerative, 86
Vestibule, 20
Vicarious menstruation, 100
Volsella, 54
Vulva, malformations of, 83
Vulvitis, 65
acute simple catarrhal, 65
chronic catarrhal, 66
croupous, 69
follicular, 70
gangrenous, 69
gonorrhœal, 66
phlegmonous, 68
Vulvo-vaginal glands, 21
cyst and abscess of, 71

J. F. Gill

WELLCOME LIBRARY INSTITUTE

J. F. Gill

NOW READY.

NEW AND REVISED ILLUSTRATED EDITIONS OF

KIMPTON'S ESSENTIAL SERIES.

ARRANGED IN QUESTION AND ANSWER FORM.

THE LATEST, CHEAPEST AND BEST

ILLUSTRATED SERIES OF COMPENDS EVER ISSUED.

THE ADVANTAGES OF QUESTIONS AND ANSWERS.—The usefulness of arranging the subject in the form of **Questions and Answers** will be apparent, since the student, in reading the standard works, often is at a loss to discover the important points to be remembered, and is equally puzzled when he attempts to formulate his ideas as to the manner in which the **Questions could be put in the Examination-Room.**

Essentials of Physiology. By H. A. HARE, M.D., Prof. Therapeutics in Jefferson Med. College, Philadelphia. Numerous illustrations. Fourth edition, revised and enlarged, containing a series of handsome plate illustrations taken from the celebrated "Icomes Nervorum Capitis" of Arnold. 192 pages. Cloth 4s. net.

Essentials of Diagnosis. By SOLOMON SOLIS COHEN, M.D., Prof. of Clin. Med. in the Philadelphia Polyclinic; and AUGUSTUS A. ESHNER, M.D., Instructor in Clin. Med. in Jefferson Med. Coll. Second edition, revised and enlarged. 419 pages. 60 illustrations, some of which are coloured, and a frontispiece. 6s. net.

Essentials of Obstetrics. By EASTERLY ASHTON, M.D., Obstetrician to Philadelphia Hospital. 75 illustrations. Fourth edition, thoroughly revised and enlarged. 256 pages. Cloth, 4s. net.

Essentials of Gynæcology. By EDWIN B. CRAIGIN, M.D., Gynæcologist to Roosevelt Hosp., New York. 200 pages. 62 fine illustrations. Fourth edition, revised. Cloth, 4s. net.

Essentials of Diseases of the Skin, including the Syphilodermata. By HENRY W. STELWAGON, M.D., Ph.D., Lect. on Dermatology in Jefferson Med. Coll. Fourth edition, revised and enlarged, with 72 letterpress cuts and 15 half-tone illustrations. 276 pages. Cloth, 4s. net.

Essentials of Histology. By LOUIS LEROY, M.D., Professor of Histology and Pathology, Vanderbilt University, Nashville, Tennessee. 255 pages, with 72 illustrations. Cloth, 4s. net.

Essentials of Refraction and Diseases of the Eye. By EDWARD JACKSON, A.M., M.D., Prof. Dis. of Eye in the Philadelphia Polyclinic. New edition. In preparation.

Essentials of Diseases of the Nose and Throat. By E. BALDWIN GLEASON, M.D., Surg. to Nose, Throat, and Ear Dept., Northern Dispensary, Philadelphia. New edition. In preparation.

Essentials of Genito-Urinary and Venereal Diseases: A Manual for Students and Practitioners. By CHARLES H. CHETWOOD, M.D., Visiting Surgeon Denilt Dispensary, Depart. of Surgery and Genito-Urinary Diseases, New York. 178 pages. Illustrated. Price 4s. net.

Essentials of Diseases of Children. By WILLIAM M. POWELL, M.D. Third edition. 222 pages. Cloth, 4s. net.

Essentials of Medical Electricity. By D. D. STEWART, M.D., Chief of Neurological Clinic in the Jefferson Med. Coll.; and E. S. LAWRENCE, M.D. 65 illustrations. Cloth, 4s. net.

Essentials of Practice of Medicine. By HENRY MORRIS, M.D., late Demonstrator, Jefferson Med. Coll., Philadelphia. Numerous illustrations and a coloured frontispiece. Third edition. Cloth, 6s. net.

Essentials of Surgery. By EDWARD MARTIN, A.M., M.D, Clin. Prof. of Genito-Urinary Dis., Instructor in Operative Surg., and Lect. on Minor Surg., Univ. of Pennsylvania. Illustrated. Seventh edition, revised and enlarged. 342 pages. Cloth, 4s. net.

Essentials of Pathology and Morbid Anatomy. By C. E. ARMAND SEMPLE, B.A., M.B., Phys. to the Bloomsbury Dispensary, etc. 160 pages, 46 illustrations. Cloth, 3s. 6d. net.

Essentials of Forensic Medicine, Toxicology, and Hygiene. By C. E. ARMAND SEMPLE, B.A., M.B. 196 pages, 130 illustrations. Cloth, 4s. 6d. net.

Essentials of Bacteriology. By M. V. BALL, M.D., Bacteriologist to St. Agnes' Hospital, Philadelphia. Third edition, revised, with 81 illustrations, some in colours, and 5 plates. 218 pages. Cloth, 4s. net.

Essentials of Nervous Diseases and Insanity. By JOHN C. SHAW, M.D., Clin. Prof. of the Dis. of the Mind and Nervous System, Long Island Coll. Hosp., Med. School. 48 original illustrations. Second edition. Cloth, 4s. net.

Essentials of Diseases of the Ear. By E. B. GLEASON, S.B., M.D., Clin. Prof. of Otology, Philadelphia Med. Coll. Second edition, revised and enlarged. 206 pages, fully illustrated. Cloth, 4s. net.

Essentials of Anatomy. By FRED. J. BROCKWAY, M.D., Assistant Demonstrator of Anatomy, Coll. of Phys. and Surg., New York; and A. O'MALLEY, M.D., Instructor in Surg., New York Polyclinic. Second edition, with full-page plates. 376 pages. Cloth, 6s. net.

LONDON: HENRY KIMPTON, 13, Furnival Street, E.C.